Medical Science and Discovery
ISSN: 2148-6832

The Effect of Estrogen Hormone on Leptin Receptor in Small Intestine of Ovariectomized Rats

Özlem Özden Akkaya[1]*, Korhan Altunbaş[1]

1 Afyon Kocatepe University, Faculty of Veterinary Medicine, Department of Histology and Embryology, Afyonkarahisar, TR

*** Corresponding Author**: Özlem Özden Akkaya **E-mail:** ozlemozden@aku.edu.tr

ABSTRACT

Objective: Leptin, a 16 kDa hormone encoded by the obese (Ob) gene, is known for its role in regulating food intake, body composition, and energy expenditure. Leptin receptor expression has been demonstrated in several tissues, including the small intestine. Weight gain may occur in humans after menopause or in animals following ovariectomy. Estrogen affects leptin and leptin receptor expressions. In this study, we aimed to contribute to the etiology of obesity by investigating the effects of E2 on leptin receptors in the small intestines of ovariectomized rats as a model of postmenopausal conditions.

Materials and Methods: Bilateral ovariectomy was performed on 6-month-old Sprague-Dawley female rats. Ovariectomized rats (Ovx) were injected with 0.2 ml of sesame oil/rat/day or E2 (25 µg/rat/day) and euthanized at the 18th, 90th, or 162nd hours. Duodenum, jejunum, and ileum samples were fixed and embedded in paraffin using standard methods. The expression of leptin receptors were detected in the small intestine through immunohistochemistry.

Results: Leptin receptor expression was found in the villi and crypt epithelium of the small intestine and in Brunner's gland of the duodenum. E2 administration increased the leptin receptor expressions on the epithelium of villi and crypt in the duodenum and jejunum at the 90th hour ($p<0.05$); ileum at the 18th hour ($p<0.05$); and also on the epithelium of villi in the duodenum at the 162nd hour ($p<0.05$).

Conclusion: Our results indicate that E2 may upregulate the expression of leptin receptors in the small intestine, where glucose and other nutrients are absorbed after food intake and digestion, depending on the timing.

Keywords: Estrogen, Leptin receptor, Ovariectomized, Rat, Small intestine.

INTRODUCTION

Leptin (Ob) is produced by adipocytes (1, 2) and is transported via the blood to the hypothalamus, where it binds to the leptin receptor (Ob-R). The hormone functions primarily in the regulation of energy expenditure of the hypothalamus, food intake (3, 4), and prevention of obesity (5).

Leptin has been identified in many peripheral tissues where it is often transported from the blood via transcytosis and paracellular transport (6-9). Recent data suggest leptin could also be considered a gastrointestinal hormone (10, 11, 12). Leptin is expressed by some cells in the gastric mucosa (12, 13). One of these cells is an exocrine cell called the chief (principal) cell (12, 13) which secretes leptin and pepsinogen into the digestive juice. In addition to that, a small amount of exocrine leptin is also expressed by Parietal cells (13). Another leptin-secreting cell is small endocrine cells localized between the gastric glands. From these cells, which are in close proximity to the capillaries, leptin is released into the bloodstream (12). After food intake, leptin is secreted into the gastric lumen by Chief cells and thus carried to the intestine (14).

It is suggested that the role of leptin in the short–term control of food intake (12) and may role locally gastrointestinal tract affect intestinal functions such as sugar and peptides absorption and lipid handling (15, 16, 17) via its receptor (18). Leptin receptors are located in the apical and basolateral membranes of chief and parietal cells in the gastric mucosa (11) and enterocytes in the intestinal mucosa (12, 19, 20, 21). It was reported leptin reaches the brush border (apical membrane) binds to its receptor via gastric juice, and arrives at the basolateral membrane through the blood (19).

Research Article

Received 05-08-2023

Accepted 21-09-2023

Available Online: 23-09-2023

Issue Publication: 30-09-2023

They show paracrine effects by binding endocrine leptin to leptin receptors localized on the basolateral membrane of intestinal epithelial cells (19). Studies have shown that the leptin hormone increases the length and mucosal thickness of the small intestine, like a growth factor; shows that it plays a role in intestinal absorption functions (22, 23).

In the control of nutrition and weight gain, steroid hormones and, therefore gender differences are of great importance. Many studies have investigated the relationship of leptin or its receptor with estrogen (24, 25, 26, 27, 28). Estrogen causes changes in the production of leptin hormone by affecting the obesity (ob) gene transcription through its receptors in fat cells (29). It has been reported that women in the premenopausal period have higher serum leptin levels than men and postmenopausal women (27). Similarly, administration of estrogen hormone to postmenopausal women has been found to cause more leptin synthesis from omental adipose tissue (30, 31). Menopausal women experience an increase in body weight and fat mass (32), along with alterations in body fat distribution (33). Similarly, in cats (34) and dogs (35), there is an increase in body weight, mostly in body fat, due to increased food intake following ovariectomy. For this reason, ovariectomized rats are a frequently used method to model the postmenopausal period in studies (21, 24, 26)

In addition, estrogen hormone deficiency also affects the level of leptin receptors in some tissues (24,25,26,36). In poultry, administration of estrogen increased the expression of cOb-R mRNA in the intestines. This indicates that estrogen is also associated with the regulation of leptin receptor expression in the poultry small intestine (37). It was also reported that leptin receptor expression decreased in ovariectomized rat colon, and 17β-estradiol (E2) administration normalized the leptin receptor level (21).

The small intestines play an important role in the etiology of obesity seen in ovariectomized animals. As a result of the disappearance of the effect of steroid hormones, especially estrogen hormone, the degree of expression and therefore the sensitivity of leptin receptors localized in the small intestines decreases. Normal bowel functions and nutritional intake may be affected by this condition. While it is established that leptin and its receptor play a crucial role in regulating gastrointestinal system functions, there is a scarcity of studies demonstrating the relationship between estrogen hormone and leptin receptor in the regulation of these functions in mammals.

In this study, our aim was to contribute to the understanding of obesity etiology by investigating the impact of E2 on leptin receptors in the small intestine of ovariectomized rats, which serve as a model for postmenopausal conditions.

MATERIAL and METHODs

Ethical Statement: All procedures were approved by the Ethics Committee at Afyon Kocatepe University, Türkiye (AKÜHEK. 49-07; 25.01.2008).

Animals: Six-month-old Sprague-Dawley female rats were supplied from Department of Laboratory Animals, Gülhane Military Medical Academy Research Centre, Ankara, Türkiye were used in the present study. All animals used in the study were kept in Afyon Kocatepe University Experimental Animal Research and Application Center under standard control conditions and were fed commercial rat feed ad libitum.

Briefly, rats (total n = 36) were anesthetized by ketamine (Alfamine, Alfasan Int. BV3440 AB, Voerden Holland) (21.2 mg/kg i.p.) and xylazine (Rompun® enj, Bayer Türk Kimya San. Ltd. Sti. Istanbul) (4.2mg/kg i.p.), and underwent bilateral ovariectomy (Ovx). Small incisions were made bilaterally on the sides of the back to expose the ovaries retroperitoneally. The ovaries were clamped and removed, and the uterine tubes were ligated. The muscle and skin were then sutured.

Ovariectomized rats were administered 60 000 IU/day Penicillin G (Pfizer) for 5 days. One week after the operation, the rats were first separated into control (C, n = 18) and 17β estradiol (E2, n =18) groups then randomly divided into six subgroups as C18, C90, C162, E218, E290, E2162 (according to the hour of the experimental period on which the animals were euthanized). The experimental protocol applied in the groups is summarized in Table 1.

Immunohistochemical Staining: Duodenum, jejunum, and ileum samples were fixed immediately in 10% buffered formalin and washed with tap water, dehydrated through 70, 80, 95, and 100% alcohol, cleared in two baths of xylene and embedded in paraffin. The paraffin sections (5µ thick) were used for immunohistochemical staining. After deparaffinization and hydration, an antigen-retrieval procedure was performed to unmask the antigens by treating the samples three times in a microwave oven at 700 W for 5 min each time in 10 mM citrate buffer (pH 6).

Table 1. The experimental procedures of the control group and estrogen group in the study.

Group	Subgroup	Application	Termination of Experiment
Control	C18: (euthanasia at 18th hour)	0.2 ml/rat Sesame oil, intramuscular (i.m.)	18th hours after the application
	C90: (euthanasia at 90th hour)	0.2 ml/rat/day Sesame oil, (i.m.)	At 90th hour
	C162: (euthanasia at 162nd hour)	0.2 ml/rat/day, Sesame oil, (i.m.)	At 162nd hour
17β estradiol	E218: (euthanasia at 18th hour)	25 µg/rat/day E2 (Sigma E8875), (i.m.)	18th hours after the application
	E290: (euthanasia at 90th hour)	25 µg/rat/day E2, (i.m.)	At 90th hour
	E2162: (162nd hour)	25 µg/rat/day E2, (i.m.)	At 162nd hour

Rats were euthanized by cervical dislocation under anesthesia at the 18th, 90th, or 162nd hours respectively.

http://dx.doi.org/10.36472/msd.v10i9.1010

After cooling at room temperature, slides were treated with 3% hydrogen peroxide (H2O2) in methanol for 10 min and then washed with PBS for 3 × 5 min. The sections were incubated in blocking reagent for 10 min, and incubated overnight at 4 °C with Ob-R goat polyclonal primary antibody at a 1:25 dilution (Santa Cruz Biotechnology M-18, sc-1834). Staining was completed with a Histostain Plus Kit (Universal Dakocytomation LSAB® + Kit, Peroksidase K0690) according to the manufacturer's instructions. The color reaction product was developed with 3.3'-diaminobenzidine (DAB) (Zymed, 00-2020). All sections were counterstained with hematoxylin (21).

Immunohistochemical Evaluation

Immunohistochemical evaluation was done by investigating several aspects such as whether the target tissue was stained or not, the character of the staining (nuclear or cytoplasmic), which parts of the target tissue structures were stained, and the staining intensity. The evaluations were made by two independent observers, giving values from 0 to 3 for unstained (-), weak staining (+), moderate staining (++), and severe staining (+++) according to the characteristics (38).

Statistical Analysis

The mean and standard error values of the data obtained from the immunohistochemical evaluation were assessed, and it was determined whether the differences between the groups were statistically significant. The data of the estrogen and control groups were compared with a non-parametric Mann-Whitney U test, and the statistical differences were analyzed (*: $p \leq 0.05$). Statistical analyses of the study were performed using the SPSS 10.0 (Statistical Package for Social Sciences) program.

RESULTs

Leptin Receptor Immunoreaction in Small Intestine

Leptin receptor immunoreaction was observed in the apical cytoplasm of duodenum villi, crypt epithelium, Brunner's gland epithelial cells, connective tissue cells, and a small number of goblet cells. In the jejunum, the positive reaction for leptin receptor was observed in the apical cytoplasm of the villi and crypt epithelium, connective tissue cells, and a small number of goblet cells. Lastly, in the ileum, the positive reaction for the leptin receptor was observed in the apical cytoplasm of the villi and crypt the epithelium of the ileum, connective tissue cells, and a small number of goblet cells. In terms of leptin expression intensity, within-group variations were observed in both groups.

Duodenum

In the control group, a negative reaction was observed in the villus epithelium of the duodenum along with a negative or weak reaction in the epithelial cells at the bottom of the crypts at the 18th hour (**Figure 1 A, B**). In the estrogen group, a weak reaction was detected in the villus epithelial cells and the epithelial cells in the middle and upper portions of the crypts, while a moderate reaction was seen in some of the epithelial cells in the lower parts (**Figure 1 C, D**). At the 18th hour, a weak to moderate immunoreaction was observed in the Brunner's glands of the duodenum in the control and the estrogen groups.

In the control group, a negative reaction was observed in the villus epithelial cells of the duodenum at the 90th hour and the immunoreaction in the crypt epithelial cells were mostly negative apart from a few samples showing a very weak reaction (**Figure 2 A, B**). In the estrogen group, a weak immunoreaction was detected in the villus epithelial cells and a moderate reaction was observed in the crypt epithelial cells at the 90th hour. A weak to moderate expression was observed in the Brunner's glands of the duodenum both in the control and estrogen groups at the 90th hour (**Figure 2 C, D**).

In the control group, an immunoreaction ranging from negative to very weak was observed in the villus epithelial cells of the duodenum at the 162nd hour, while a weak reaction was detected in the villus epithelial cells in the estrogen group. In the control group, a negative to weak reaction was detected in the epithelial cells in the middle and upper portions of the duodenal crypts, while a weak reaction with a few samples showing moderate immunoreaction was observed in the epithelial cells at the bottom portion (**Figure 3 A, B**). In the estrogen group, some epithelial cells at the bottom of the crypts stained moderately, while the epithelial cells in the middle and upper portions of the crypts were negatively or weakly stained. Weak to moderate leptin receptor expression was detected in Brunner's gland epithelial cells (**Figure 3 A, B**).

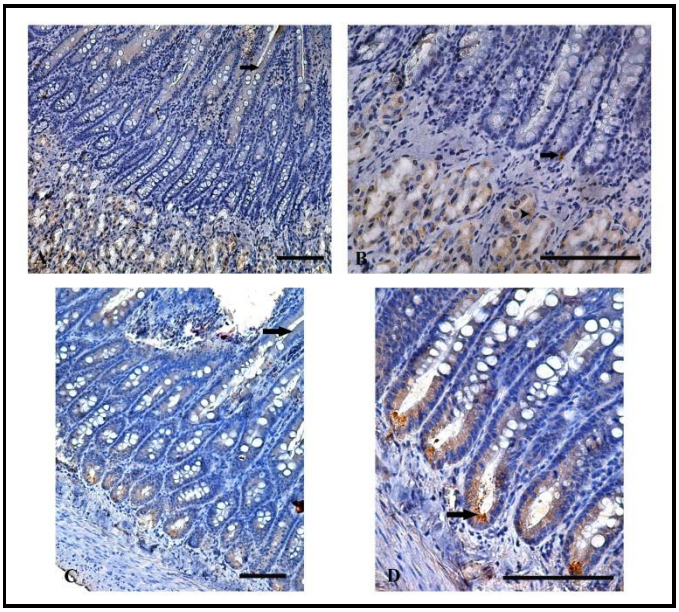

Figure 1. The leptin receptor immunoreaction in the duodenum at the 18th hour. A, B: Control group; C, D: E2 group. A: Negative immunoreaction for leptin receptor in villus epithelial cells (arrow); B: Moderate leptin receptor immunoreaction in crypt epithelial cells (arrow) and Brunner's glands (arrowhead); C: Weak leptin receptor immunoreaction in villus epithelial cells (arrow); D: Moderate leptin receptor immunoreaction in crypt epithelial cells (arrow) and Brunner's glands (arrowhead). Bar =100 µm.

http://dx.doi.org/10.36472/msd.v10i9.1010

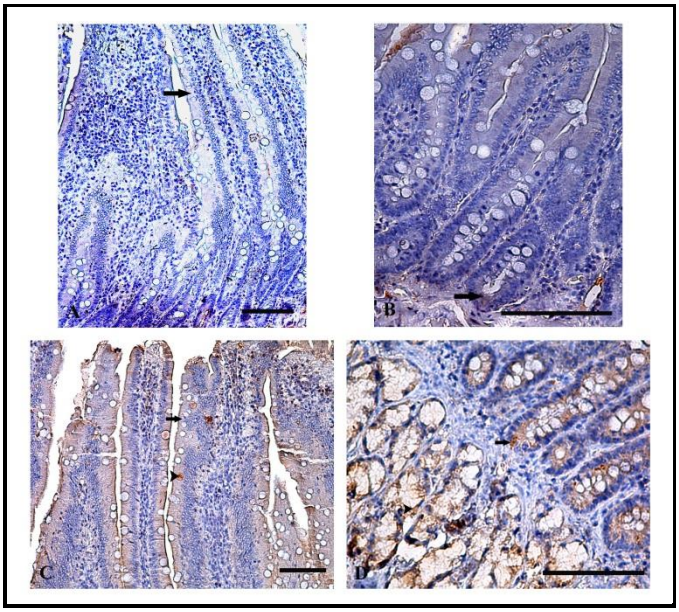

Figure 2. The leptin receptor immunoreaction in the duodenum at the 90th hour, A, B: Control group; C, D: E2 group. A: Negative immunoreaction for leptin receptor in villus epithelial cells (arrow); B: Very weak leptin receptor immunoreaction in crypt epithelial cells (arrow); C: Weak leptin receptor immunoreaction in villus epithelial cells (arrow) and the leptin receptor immunoreaction in Goblet cells (arrowhead); D: Moderate leptin receptor immunoreaction in crypt epithelial cells (arrow) and Brunner's glands (arrowhead). Bar =100 µm.

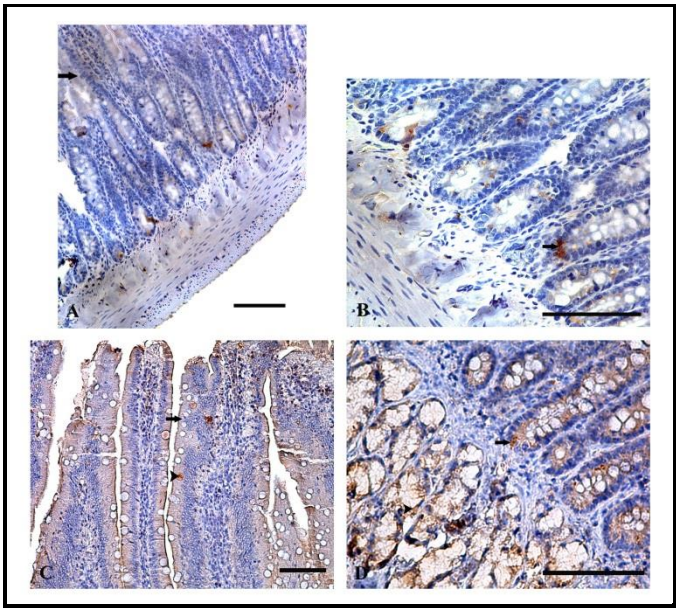

Figure 3. The leptin receptor immunoreaction in the duodenum at the 162nd hour. A, B: Control group; C, D: E2 group. A: Very weak leptin receptor immunoreaction in villus epithelial cells (arrow); B: Moderate leptin receptor immunoreaction in crypt epithelial cells (arrow); C: Weak leptin receptor immune reaction in villus epithelial cells (arrow); D: Moderate leptin receptor immunoreaction in crypt epithelial cells (arrow). Bar =100 µm.

Jejunum

In the control group, negative immunoreactions were observed both in the villus epithelial cells of the jejunum and the crypt epithelial cells at the 18th hour along with some samples showing weak reactions (**Figure 4 A, B**). In the estrogen group, negative immunoreactions were observed in the villus epithelial cells and negative or weak immunreactions were determined in the cells of the middle and upper parts of the crypt epithelium. In addition to that, a moderate immunoreaction was seen in the lower parts of the crypt epithelium (**Figure 4 C, D**).

While a weak reaction was observed in the villus epithelial cells of the jejunum at the 90th hour of the control group, a negative or weak immunoreaction was detected in the epithelial cells of the crypts, and a moderate immunoreaction in some epithelial cells was observed in the bottom parts (**Figure 5 A, B**). In the estrogen group, a varying range of immunoreactions was observed from weak to severe reactions in the villus epithelial cells, while a moderate reaction was observed in the middle and upper epithelial cells of the crypts, and a severe reaction was observed in some epithelial cells in the lower parts (**Figure 5 C, D**).

In the control group, the villus epithelial cells of the jejunum were stained negatively, while a weak to moderate reaction was detected in the villus epithelial cells of the estrogen group at the 162nd hour (**Figure 6 A, C**). Leptin receptor immunoreaction was also detected in connective tissue cells (Figure 6 A, C). A weak reaction was observed in the crypt epithelial cells of the control group, while a moderate expression was detected in the crypt epithelial cells in the estrogen group (**Figure 6 B, D**).

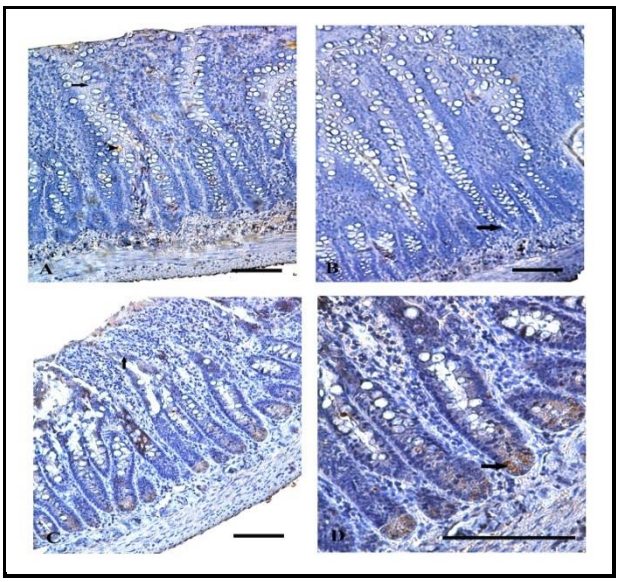

Figure 4. The leptin receptor immunoreaction in the jejunum at the 18th hour. A, B: Control group; C, D: E2 group. A: Negative immunoreaction for leptin receptor in villus epithelial cells (arrow) and the leptin receptor immunoreaction in Goblet cells (arrowhead); B: Negative immunoreaction for leptin receptor in crypt epithelial cells (arrow); C: Negative immunoreaction for leptin receptor in villus epithelial cells (arrow); D: Moderate leptin receptor immunoreaction in crypt epithelial cells (arrow). Bar =100 µm.

http://dx.doi.org/10.36472/msd.v10i9.1010

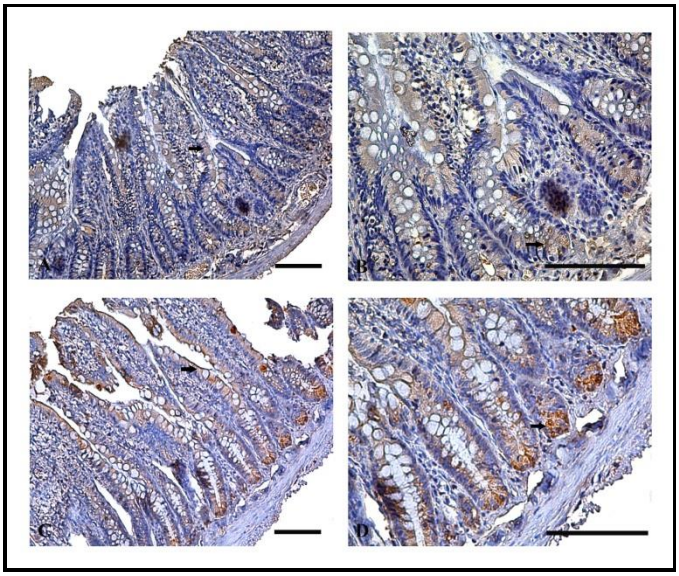

Figure 5. The leptin receptor immunoreaction in the duodenum at the 90th hour. A, B: Control group; C, D: E2 group. A: Weak leptin receptor immunoreaction in villus epithelial cells (arrow); B: Moderate leptin receptor immunoreaction in crypt epithelial cells (arrow); C: Moderate leptin receptor immunoreaction in villus epithelial cells (arrow); D: Moderate leptin receptor immunoreaction in crypt epithelial cells (arrow). Bar =100 µm.

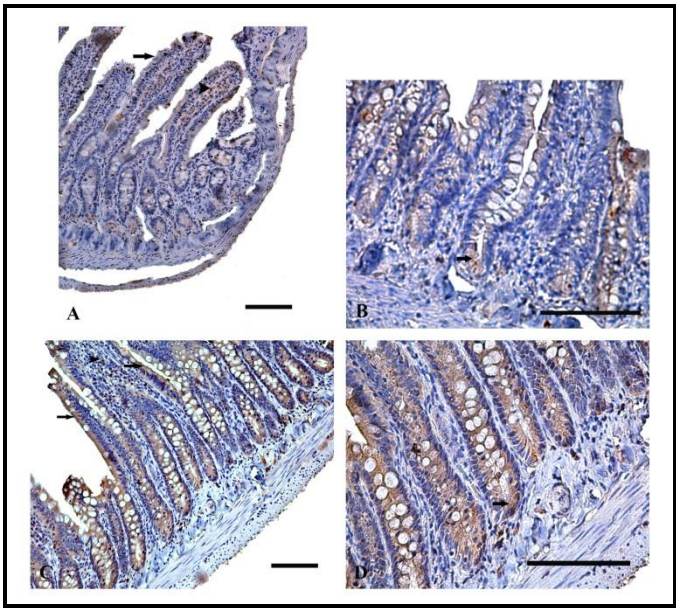

Figure 6. The leptin receptor immunoreaction in the jejunum at the 162nd hour. A, B: Control group; C, D: E2 group. A: Negative immunoreaction for leptin receptor in villus epithelial cells (arrow) and leptin receptor immunoreaction in connective tissue cells (arrowhead); B: Weak leptin receptor immunoreaction in crypt epithelial cells (arrow); C: Moderate leptin receptor immunoreaction in villus epithelial cells (arrow) and leptin receptor immunoreaction in connective tissue cells (arrowhead); D: Moderate leptin receptor immunoreaction in crypt epithelial cells (arrow) Bar =100 µm.

Ileum

A negative reaction was observed in the villi and the crypt epithelial cells of the ileum at the 18th hour of the control group (**Figure 7 A, B**). In the estrogen group, a moderate reaction in was observed in the villus epithelial cells, while a weak immunoreaction was detected in the crypt epithelium cells in general, and a moderate immunoreaction was seen in some epithelial cells at the bottom (**Figure 7 C, D**).

In the ileum tissue, an immunoreaction ranging from negative to weak was observed in the villus epithelial cells of the control and estrogen groups at the 90th hour. In the control and estrogen groups, a moderate to severe reaction was detected only in the epithelial cells at the bottom of the crypts (**Figure 8**)

In the control group, the villus epithelial cells of the ileum tissue showed a weak immunoreaction but, in some samples, the reaction was moderate at the 162nd hour, while a very weak immunoreaction was detected in the crypt epithelium (**Figure 9 A, B**). In the estrogen group, the immunoreaction in the villus epithelial cells was either negative or very weak, while a moderate immunoreaction was only detected in epithelial cells lining the bottom parts of the crypts (**Figure 9 C, D**).

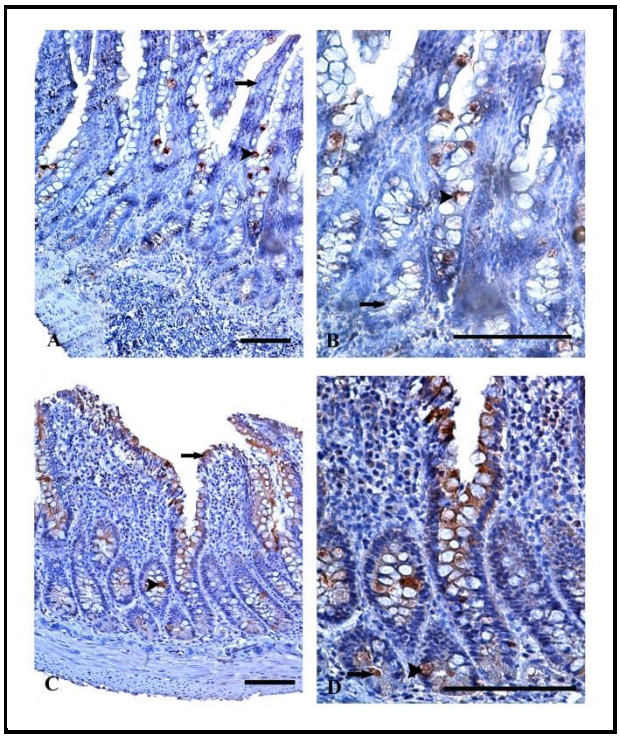

Figure 7. The leptin receptor immunoreaction in the ileum at the 18th hour. A, B: Control group; C, D: E2 group. A: Negative immunoreaction for the leptin receptor in villus epithelial cells (arrow) and the leptin receptor immunoreaction in Goblet cells (arrowhead); B: Negative immunoreaction for the leptin receptor in crypt epithelial cells (arrow) and the leptin receptor immunoreaction in Goblet cells (arrowhead); C: Moderate leptin receptor immunoreaction in crypt epithelial cells (arrow) and the leptin receptor immunoreaction in Goblet cells (arrowhead); D: Moderate leptin receptor immunoreaction in crypt epithelial cells (arrow) and the leptin receptor immunoreaction in Goblet cells (arrowhead) Bar =100 µm.

http://dx.doi.org/10.36472/msd.v10i9.1010

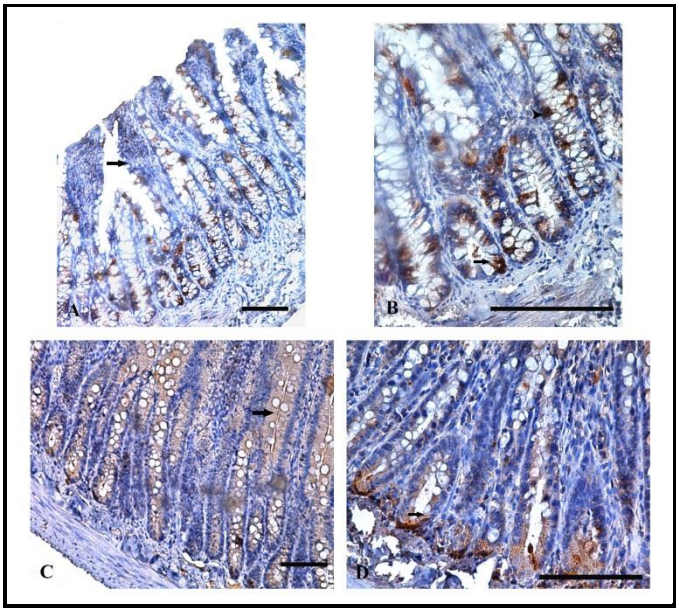

Figure 8. The leptin receptor immunoreaction in the ileum at the 90th hour. A, B: Control group; C, D: E2 group. A: Weak leptin receptor immunoreaction in villus epithelial cells (arrow); B: Moderate leptin receptor immunoreaction in crypt epithelial cells (arrow) and the leptin receptor immunoreaction in Goblet cells (arrowhead); C: Weak leptin receptor immunoreaction in villus epithelial cells (arrow); D: Severe leptin receptor immunoreaction in crypt epithelial cells (arrow). Bar =100 µm.

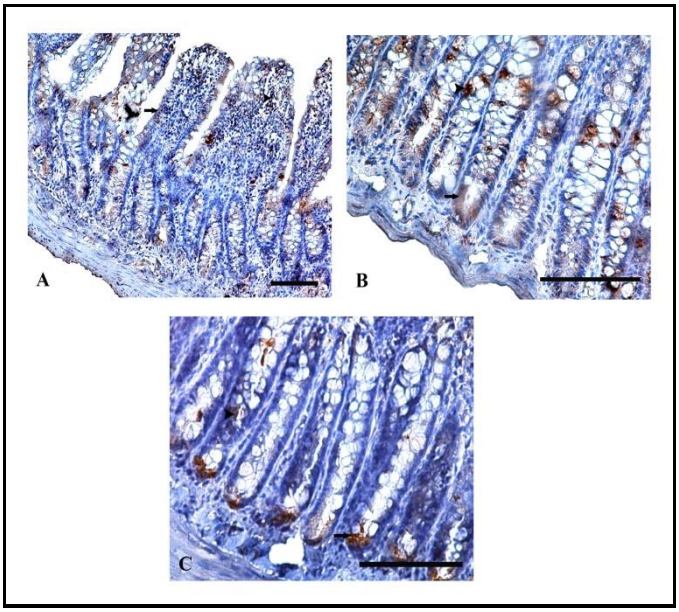

Figure 9. The leptin receptor immunoreaction in the ileum at the 162nd hour. A, B: Control group; C, D: E2 group. A: Weak leptin receptor immunoreaction in villus epithelial cells (arrow) and the leptin receptor immunoreaction in connective tissue cells (arrowhead); B: Weak leptin receptor immunoreaction in crypt epithelial cells (arrow) and the leptin receptor immunoreaction in Goblet cells (arrowhead); C: Weak leptin receptor immunoreaction in villus epithelial cells (arrow) and the leptin receptor immunoreaction in Goblet cells (arrowhead); B: Severe leptin receptor immunoreaction in crypt epithelial cells (arrow) and the leptin receptor immunoreaction in Goblet cells (arrowhead). Bar =100 µm.

Effect of E2 on Leptin Receptor in the Small Intestine

In the ovariectomized rats, E2 administration increased the leptin receptor expressions on the epithelium of villi and crypt in duodenum (villi, C90: 0.00±0.00 and E290: 0.80 ± 0.20; crypt, C90: 0.33 ± 0.33 and E290: 1.90 ± 0.40) and jejunum (villi, C90: 0.50 ± 0.28 and E290: 1.70 ± 0.30; crypt, C90: 0.62 ± 0.23 and E290: 2.00 ± 0.31) at 90 hours ($p<0,05$) (Table 2,3); and ileum (villi, 0.00 ± 0.00 and 2.00±0.40; crypt, C18: 0.00 ± 0.00 and E218: 1.50±0.28) at 18 hours ($p<0.05$) (Table 4); and also, on the epithelium of villi in duodenum (C162: 0.25±0.25 and E2162: 1.00 ± 0.00) at 162 hours ($p<0.05$) (Table 2, 3, 4).

Table 2: Effect of E2 on duodenum leptin receptor expression at 18th, 90th and 162nd hours in ovariectomized (Ovx) rats.

Parameters	Villi	Crypt	Brunner's gland
C18	0.00 ± 0.00	0.83 ± 0.60	1.50 ± 0.28
E218	0.66 ± 0.33	2.16 ± 0.60	1.66 ± 0.33
P	0.217	0.127	0.637
	Villi	**Crypt**	**Brunner's gland**
C90	0.00±0.00	0.33 ± 0.33	1.50 ± 0.28
E290	0.80 ± 0.20	1.90 ± 0.40	1.50 ± 0.50
P	0.040*	0.046*	0.817
	Villi	**Crypt**	**Brunner's gland**
C162	0.25±0.25	0.50 ± 0.28	1.50 ± 0.28
E2162	1.00 ± 0.00	1.10 ± 0.10	1.87 ± 0.12
P	0.025*	0.079	0.317

Statistical differences were analyzed with a Mann–Whitney U-test(* $P<0.05$).

Table 3: Effect of E2 on jejunum leptin receptor expression at 18th, 90th. and 162nd. hours in ovariectomized (Ovx) rats

Parameters	Villi	Crypt
C18	0.00 ± 0.00	0.33 ± 0.33
E218	0.00 ± 0.00	1.33 ± 0.33
P	1.000	0.099
	Villi	Crypt
C90	0.50 ± 0.28	0.62 ± 0.23
E290	1.70 ± 0.30	2.00 ± 0.31
P	0.039*	0.022*
	Villi	Crypt
C162	0.00±0.00	0.75 ± 0.25
E2162	1.60 ± 0.40	1.70 ± 0.30
P	0.180	0.059

Statistical differences were analyzed with a Mann–Whitney U-test (* P<0.05).

Table 4: The effect of E2 on ileum leptin receptor expression at 18th , 90th and 162nd hours in ovariectomized (Ovx) rats.

Parameters	Villi	Crypt
C18	0.00 ± 0.00	0.00±0.00
E218	2.00±0.40	1.50±0.28
P	0.026*	0.025*
	Villi	Crypt
C90	0.33±0.33	2.33±0.33
E290	0.50±0.28	2.50±0.28
P	0.683	0.683
	Villi	Crypt
C162	1.00±0.20	0.75±0.25
E2162	0.33±0.33	2.00±0.00
P	0.138	0.128

Statistical differences were analyzed with a Mann–Whitney U-test(* P<0.05).

DISCUSSION

To investigate the impact of estrogen hormone on the leptin receptor, we employed an experimental model of ovariectomized rats. Ovariectomized rat model is widely used in experimental studies on female sex hormones. Although, more than 20 estrogens have been identified in mammals, estradiol is the most abundant and the most effective (39). In studies on both leptin hormone and other agents in ovariectomized rats, 10-50 µg/rat/day doses of 17-B estradiol were used. (25, 26, 36). In addition, in studies on estrogen, it has been determined that the effects of estrogen in tissues occur approximately in the 18th hour (40). In light of these reports, in this study, 17β-estradiol was administered in ovariectomized rats at a dose of 25 µg/rat/day, and at the same time, to determine the effect of the application time, leptin receptor expirations in the small intestines were observed at the 18th, 90th and 162nd hours.

Leptin is secreted by the chief, parietal, and endocrine cells of the stomach and binds with the leptin receptor that is localized in different parts of the small intestine. Immunohistochemical techniques could be used to confirm the presence of leptin receptors in the mucosa of small intestinal segments. In our study, only intracytoplasmic staining was observed in enterocytes of both villi and crypts by immunohistochemistry. In previous studies, leptin receptors especially had been reported in apical and basolateral membranes (12, 19, 41), in addition to Barrenetxe et al.'s work which showed a lining of intracytoplasmic staining in the intestinal villi and crypts (19).

Our study detected only intracytoplasmic expression, not membranous expression in villi and crypt epithelium. This case results from after leptin binding to receptors, endocytosis, and vesicle traffic in the cell. Nevertheless, variations in fixatives, species, and antibodies are also crucial factors that can contribute to disparities between different studies. For instance, Barrenetxe et al. observed divergent leptin receptor expressions within the same species, and the fixatives used for tissue fixation varied. Additionally, the utilization of antibodies targeting either the N or C-terminal leptin receptor is a pivotal factor that may also lead to discrepancies. Contrary to our findings, despite using the same primary antibody as our study, Buyse et al., reported leptin expressions in the apical membranes in frozen sections (17). It is assumed that this localisation difference might have arisen due to using paraffin or frozen sections.

In this study, the reaction was strong at the deeper layer of crypts but was weaker in villi and the upper layer of crypts. It is known that the deeper layer of crypts contains the proliferative matrix cells. This may suggest that leptin could also be a proliferation factor in the small intestine. Alavi et al. also suggested that leptin may be a growth factor for the small intestine. On the contrary, it was claimed by other researchers that leptin has no effect on proliferation in small intestine and colon crypts (42).

Leptin receptor expression was showed in Brunner's glands of the duodenum and goblet cells of the intestine. In addition, epidermal growth factor, one of the important growth factors, is produced in Brunner's glands (43). Leptin and the epidermal growth factor in Brunner's glands can regulate proliferation and nutritional status. Studies in the colon showed that luminal leptin increases mucin secretion from goblet cells (44, 45). It has been emphasized that the effect of leptin on mucus secretion is initiated by binding to leptin receptors expressed in the apical and basolateral parts of the colonic cell membranes of luminal and systemic leptin (44). Our data showed that the increase of mucin secretion is not only related to leptin receptors in enterocytes, but leptin receptors expressed in goblet cells also may regulate mucin secretion.

We observed positive reactions in a few connective tissue cells mainly in the jejunum. Leptin is found in immune cells like granulocytes and macrophages in lamina propria of rats jejunum (15). Therefore, leptin may have a role in immune function in the mucosa of the small intestine.

Hypothalamus has a significant role in revealing the specific effects of leptin. Previously, leptin receptors were localized in estrogen receptors α and β (ER α and β) expressing cells in the hypothalamus, and it was suggested that these receptors were acting in coordination (26). Leptin receptor's colocalization with ER α is reported to be 100% but with ER β the colocalization rates were found only 15% in dorsal root ganglion neurons. It is declared that estrogen increases leptin receptor mRNA expressions through ER α mediation (25). Estrogen receptors are known to exist in small intestinal epithelial cells. This data suggests that estrogen may also affect the leptin receptor expression of small intestinal epithelial cells. (46). In chicken, cOb-R mRNA did not change during sexual maturation in most tissues whereas mRNA levels increase in the intestine. However, estrogen treatment enhances Ob-R mRNA expressions in the intestine of chicken. In addition, while estrogen administration increases the expression of cOb-R mRNA in the intestines, it does not change its expression in other tissues. It has been claimed that estrogen is also associated with the regulation of leptin receptor expression in the poultry small intestine and that there may be a correlation between gonadal and metabolic functions (37).

In this study, it was observed that estrogen causes an increase in leptin receptor expressions in all small intestine crypts and villi except at the 18th hour in the jejunum and 162nd hours in the ileum. We determined statistically significant increased reaction intensities between groups only crypt and villi of ileum at the 18th hours, jejunum and duodenum at the 90th hour, and villi of the duodenum at the 162nd hours. The fact that significant effects occurred earlier in the ileum than in other parts of the intestine suggests that estrogen may affect the intestinal parts differently. On the other hand, it appears that application times also play a role in the different effects of estrogen on the leptin receptor. Alonso et al. (2007) reported that the short-term administration of estrogen in adipocytes of ovariectomized rats initially reduced leptin receptor expression, followed by an increase in expression in the subsequent days, and long-term (chronic) administration ultimately led to a decrease in expression (24). In the short-term estrogen administration, we observed increased leptin receptors expressions in the ileum, and at 90th hour expression levels raised in the jejunum and duodenum. Estrogen can modulate the leptin receptors in the small intestine in a time and tissue-dependent way. Previous studies have also reported that the effects of estrogen vary depending on duration (46, 47, 48).

While estrogen significantly increased the expression of the leptin receptor in the villi and crypt earlier, these effects appeared later in the duodenum and jejunum.

In summary, E2 may upregulate the expression of leptin receptors in the small intestine, where glucose and other nutrients are absorbed after food intake and digestion, depending upon the time. The results of this study show that the effects of estrogenic agents on the leptin receptor in the small intestine vary according to intestinal segments and time-dependent

CONCLUSION

Our findings may offer a new field of investigation for the effects of estrogen on leptin and its receptor in the gastrointestinal tract. However, applications at different time intervals are needed to determine the time-dependent effects of estrogen on the regulation of leptin receptor expression in the small intestine.

Acknowledgements: This study was supported by Commission of Scientific Research Projects, Afyon Kocatepe University, Türkiye (07.VF.07). This study was presented at the 9th National Histology and Embryology Congress, May 20-23, Adana, Türkiye

Conflict of interest: The authors declared no potential conflicts of interest with respect to the research, authorship, and/or publication of this article.

Author Contributions: ÖÖA, KA; contributed to the conception of the work, execution of the study, revision of the draft, **ÖÖA;** approval of the final manuscript version, and concur with all aspects of the work. All authors have reviewed the manuscript, and affirm that they fulfill the ICMJE criteria for authorship.

Ethical approval: All procedures followed were in accordance with the ethical standards of the responsible committee on human experimentation (institutional and national) and/or with the Helsinki Declaration of 1964 and later versions. Ethics Statement: All procedures were approved by the Afyon Kocatepe University Ethics Committee (AKÜHEK. 49-07; 25.01.2008).

REFERENCES

1. Hamilton BS, Paglia D, Kwan AYM, Deitel M. Increased obes mRNA expression in omental fat cells from massively obese humans. Nature Med 1995;1:953-6.

2. Zhang Y, Proenca R, Maffei M, Barone M, Leopold L, Friedman JM. Positional cloning of the Mouse obese geneand its human homologue. Nature 1994;372: 425-32.

3. Halaas JL, Gajawala KS, Maffei M, Cohen SL, Chait BT, Rabinowitz D, Lallone, RL, Burley SK, Friedman JM. Weight – reducing effects of the plasma protein encoded by the obese gene. Science 1995;269:543-6.

4. Pelleymounter MA, Cullen MY, Baker MB. Effects of the obese gene product on body weight regulation in ob/ob mice. Science 1995;269:540-3.

5. Friedman JM, Halas JL. Leptin and the regulation of body weight in mammals. Nature 1998;395:763-9.

6. Hassink SG, de Lancey E, Sheslow DV, Smith-Kirwin SM, O'Connor DM, Considine RV, Opentanova I, Dostal K, Spear ML, Leef K, Ash M, Spitzer AR, Funanage VL. Placental leptin: an important new growth factor in intrauterine and neonatal development? Pediatrics 1997;100: E1.

7. Gonzalez RR, Caballero-Campo P, Jasper M, Mercader A, Devoto L, Pellicer A, Simon C. Leptin and Leptin Receptor Are Expressed in the Human endometrium and endometrial leptin secretion is regulated by the human blastocyst. J Clin Endocrinol Metab 2000; 85(12):4883-8.

8. Wang J, Lie R, Hawkins M, Barzalai N, Rosetti L. A nutrient – sensing pathway regulates leptin gene expression in muscle and fat. Nature 1998;393:684-8.

9. Casabielle X, Hawkins M, Tome MA, Peino R, Dieguez C, Casanueava FF. Presence of leptin in colostrum and/or breast milk from lactating mothers: a 63 potential role in the regulation of neonatal food intake. J Clin Endocrinol Metab 1997;8: 4270-3.

10. Cinti S, Matteis RD, PicoÂ C, Ceresi E, Obrador A, Maffeis C, Oliver J, Palou A. Secretory granules of endocrine and chief cells of human stomach mucosa contain leptin Int J Obes Relat Metab Disord 2000;24;789-93.

11. Mix H, Widjaja A, Jandl O. Expression leptin and leptin receptor isoforms in the human stomach. Gut 2000;47:481-6.

12. Cammisotto PG, Renaud C, Gingras D, Delvin E, Levy E, Bendayan M. Endocrine and exocrine of leptin by the gastric mucosa. J Histochem Cytochem 2005; 53(7);851-860.

13. Sobhani I, Bado A, Visszaine C, Buyse M, Kermorgant S, Laigneau JP, Attoub S, Lehy T, Henin D, Mignon M, Lewin MJ. Leptin secretion leptin receptor in the human stomach. Gut 2000;47:178-83.

14. Bado A, Sandrine L, Samir A, Kermorgant S, Laigneau JP, Bortoluzzi MN, Moizo L, Lehy T, Guerre-Millo M, Le Marchand-Brustel Y, Lewin MJ. The stomach is a source of leptin. Nature 1998;394:790-3

15. Lostao M.P, Urdaneta E, Martinez –Anso E, Barber A, Martinez JA. Presence of leptin receptor in rat small intestine and leptin effect on sugar absorption. FEBS Lett 1998;423;302-6.

16. Morton NM, Emilsson V, Liu YL, Cawthorne MA. Leptin action in intestinal cells. J Biol Chem 1998;273:40, 26194-201.

17. Buyse M, Berlioz F, Guilmeau S, Tsocas A, Voisin T, Péranzi G, Merlin D, Laburthe M, Lewin MJ, Rozé C, Bado A. PepT1-mediated epithelial transport of dipeptides and cephalexin is enhanced by luminal leptin in the small intestine. J Clin Invest. 2001:108(10): 1483-94.

18. Tartaglia LA, Dembski M, Weng X, Deng NH, Culpepper J, Devos R, Richards GJ, Campfield LA, Clark FT, Deeds J, Muir C, Sanker S, Moriarty A, Moore KJ, Smutko JS, Mays GG, Wool EA, Monroe CA, Tepper RI. İdentification and expression cloning of a leptin receptor, OB-R. Cell 1995;83:1263-71.

19. Barrenetxe J, Villaro AC, Guembe L, Pascual I, Munoz-Navas M, Barber A, Lostao MP. Distribution of the long leptin receptor isoform in brush border, basolateral membrane, and cytoplasm of enterocytes. Gut 2002;50:797-802.

20. Sferra R, Pompili S, Cappariello A, Gaudio E, Latella G, Vetuschi A. Prolonged Chronic Consumption of a High Fat with Sucrose Diet Alters the Morphology of the Small Intestine. Int J Mol Sci 2021;22(14):7280.

21. Yildiz M, Altunbas K. Effect of 17β-oestradiol on the leptin receptor expression in the colon of ovariectomized rats. Revue Méd Vét 2013;164(10):457-63.

22. Wolinski J, Biernat M, Guilloteau P, Westrom BR, Zabielski R. Exogenous leptin controls the develop.ment of the small intestinein neonatal piglets. J Endocrinol. 2003;177:215-22.

23. Alavi K, Schwartz MZ, Prasad R, O'connor D, Funanage V. Leptin: a new growth factor for the small intestine. J Pediatr Surg 2002;37:327-30.

24. Alonso A, Fernandez R, Moreno M, Ordonez P, Diaz F, Gonzalez C. Leptin and its receptor are controlled by 17beta- estradiol in peripheral tissue of ovariectomized rats. Exp Biol Med 2007;232:542-549.

25. Chen HP, Fan J, Cui S. Detection and estrogen regulation of leptin receptor expression in rat dorsal root gangliyon. Histochem Cell Biol 2006;126:363-9.

26. Meli R, Pacilio M, Mattace G, Esposito E, Coppola A, Nasti A, Di Carlo C, Nappi C, Di Carlo R. Estrogen and raloxifene modulates leptin and its receptor in hypothalamus and adipose tissue from ovariectomized rats. Endocrinology 2004;145:3115-21.

27. Shimizu H, Shimomura Y, Nakanishi Y, Futawatari T, Ohtani K, Sato N, Mori M. Estrogen increases invivo leptin production in rats and human subject. J Endocrinol 1997;154:285-92

28. Thorn SR, Meyer MJ, Van Amburgh ME, Boisclair YR. Effect of estogen on leptin and expression of leptin receptor transcripts in prepubertal dairy heifers. J Dairy Sci 2007;90:3742-50.

29. Machinal F, Dieudonne MN, Leneveu MC, Pecquery R, Giudicelli Y. In Vivo and in Vitro ob Gene Expression and Leptin Secretion in Rat Adipocytes: Evidence for a Regional Specific Regulation by Sex Steroid Hormones. Endocrinology 1999;140(4): 1567-74.

30. Chen F, Lee N, Soong Y. Changes in the lipoprotein profile in postmenopausal women receiving hormone replacement therapy. J Reprod Med 1998;43:568.

31. Cheugn AP. Acuta effects of estradiol and progesterone on insulin, lipids and lipoproteins in postmenopausal women: A pilot study. Maturitas 2000;35:45.

32. Burger HG, Dudley EC, Hopper JL. The Endocrinology of the menopausal transition: A cross- sectional study of a population – based sample. J Clin Endocrinol Metab 1995;80:3537-40.

33. Hassager C, Christiansen C. Estragen / Gestagen theraphy changes soft tissue body composition in postmenopausal women. Metabolism 1989;38:662-5.

34. Martin L, Siliart B, Dumon H, Backus R, Biourge V, Nguyen P. Leptin, body fat content and energy expenditure in intact and gonadectomized adult cats: a preliminary study. J Anim Physiol Anim Nutr 85 2001;85(7-8):195–99.

35. Houpt KA, Coren B, Hintz HF, Hilderbrant JE. Effect of sex and reproductive status on sucrose preference, food intake, and body weight of dogs. J Am Vet Med Assoc 1979;174:1083–85.

36. Kimura M, Irahara M, Yasui, T, Saito S, Tezuka M, Yamano. S, Kamada M, Aono T. et al. The obesity in bilateral ovariectomized rats is related to a decrease in the expressionof leptin receptors in the brain. Biochem Biophys Res. Commun 2002;290:1349-53.

37. Ohkubo T, Tanaka M, Nakashima K. Structure and tissue distribution of chicken leptin receptor (cOb-R) mRNA. Biochim Biophys Acta. 2000;1491:303-308

38. Fromowitz FB, Viola MV, Chao S, Oravez S, Mishriki Y, Finkel G, Grimson R, Lundy J. Ras 21 expression in the progression of breast cancer. Human Pathology 1987;18:1268-75.

39. Almey A, Milner TA, Brake WG. Estrogen receptors in the central nervous system and their implication for dopamine-dependent cognition in females. Horm Behav. 2015;74:125–38.

40. Mcneill AM, Zhang C, Stanczyk, Duckles SP, Krause DN. Estrogen Increases Endothelial Nitric Oxide Synthase via Estrogen Receptors in Rat Cerebral Blood Vessels. Stroke 2002;33:1685-91

41. Aparicio T, Kermorgant S, Darmoul D, Guilmeau S, Hormi K, Mahieu-Caputo D, Lehy T. Leptin and Ob-Rb receptor ısoform in the human digestive tract during fetal development. J Clin Endocrinol Metab 2005;90(11):6177-6184

42. FitzGread AJ, Mandir N, Goodlad RA. Leptin, cell proliferation and criypt fission in the gastrointestinal tract of intravenously fed rats. Cell Prolif 2005;38:25-33

43. Poulsen SS, Nexo E, Olsen PS, Hess J, Kirkegaard P. Immunohistochemical localization of epidermal growth factor in rat and man. Histochemistry 1986;85:389-94

44. Plaisancie P, Ducroc R, Homsi ME, Tsocas A, Guilmeau S, Zoghbi S, Thibaudeau O, Bado A. Luminal leptin activites mucin-secreting goblet cells in the large bowel. Am J Physiol Gastrointest Liver Physiol 2006;290:805-12.

45. Homsi ME, Ducroc R., Claustre J, Jourdan G, Gertler A, Estienne M, Bado A, Scoazec JY, Plaisancié P. Leptin modulates the expression of secreted and membrane associated mucins in colonic epithelial cells by targeting PKC, PI3K, and MAPK pathways. Am J Physiol Gastrointest Liver Physiol 2007;293(1) :G365-73.

46. Thomas ML, XU X, Norfleet AM, Watson CS. The presence of functional estrogen receptrors in intestinal epithelial cells. Endocrinology 1993;132:426-30.

47. Fernández-Ruiz JJ, Amor, JC, Ramos JA. Time-dependent effects of estradiol and progesterone on the number of striatal dopaminergic D2-receptors. Brain Res.1989; 476:388-95.

48. Schäfers C, Teigeler M,, Wenzel A, Maack G, Fenske M, Segner H. Concentration- and Time-dependent Effects of the Synthetic Estrogen, 17a-ethinylestradiol, on Reproductive Capabilities of the Zebrafish, Danio rerio. J Toxicol Environ Health A 2007;70(9):768-77.