

Determination of Lesion Localization with Intraoperative Gamma Probe in the Presence of a Primary Parathyroid Lesion with Early Wash-Out in Radionuclide

Sule Ceylan^{1*}

¹ University of Health Sciences Gaziosmanpasa Training and Research Hospital, Department of Nuclear Medicine, Istanbul, TR

* Corresponding Author: Sule Ceylan E-mail: ceylansule2003@gmail.com

ABSTRACT

Objective: In this research, we aimed to evaluate the success of the minimally invasive surgical method performed with intraoperative gamma-probe despite early wash-out in solitary primary parathyroid lesions and to contribute to the literature on this subject.

Methods: This retrospective study included 48 adult patients diagnosed with hyperparathyroidism, with an average parathormone value of 105 pg/mL (range: 82-127 pg/mL). Radionuclide imaging was conducted using Tc-99m sestamibi and Tc-99m-pertechnetate. Minimally invasive surgery with an intraoperative gamma probe was planned for patients with primary parathyroid lesions and surgical indications. At the conclusion of the operation, count equalization was observed in all four quadrants.

Results: Minimally invasive surgery was performed on 42 patients with the assistance of an intraoperative gamma probe. In 6 patients, the procedure was extended to conduct a four-gland exploration due to early wash-out. Each patient had one pathological lesion removed, all of which were histopathologically confirmed as parathyroid adenomas. Among the 6 patients with extended surgeries, 4 experienced early wash-out, and all 6 had been diagnosed with multinodular goiter.

Conclusion: In cases with primary hyperparathyroidism, it is aimed to remove the pathological lesion with minimally invasive surgery and leave the glands that continue their normal function in place. Preoperative localization methods help the surgeon in this regard, but pathologies in the surrounding tissue can reduce the success of minimally invasive surgery.

Keywords: sestamibi, parathyroid scintigraphy, primary parathyroid lesions

Research Article

Received 01-09-2023

Accepted 11-09-2023

Available Online: 11-09-2023

Issue Publication: 30-09-2023

Distributed under
Creative Commons CC-BY-NC 4.0

OPEN ACCESS



INTRODUCTION

Thyroid ultrasonography (USG) and Tc-99m sestamibi parathyroid gland scintigraphy (PS) are the most frequently used methods for the diagnosis and localization of primary parathyroid lesions (PPL). Minimally invasive surgery (MIS) may be preferred in lesions that can be localized pre-operatively if surgery is indicated (1-3).

In lesions that cannot be found with MIS, the operation can be expanded, and four gland explorations can be performed. The sensitivity of PS in diagnosing parathyroid adenomas has been reported to be 91% and specificity as 98.8% (4). With the help of preoperative noninvasive localization methods and intraoperative gamma probe (IGP), PPLs can be extracted successfully with MIS.

Late radionuclide accumulation in PPL in PS is the expected finding. In some cases, while imaging continues, activity in PPL washes out at a rate similar to the surrounding tissue. In our study, we aimed to evaluate the success of the IGP-guided MIS method in PPL patients who underwent early wash-out and to contribute to the literature on this subject.

MATERIAL and METHODS

48 adult patients were included in this retrospective study. The mean age of the patients was 44 (37-51).

- Out of these patients, 30 (62.5%) were women.
- All patients presented with hyperparathyroidism (HP).
- The average parathormone (PTH) value was 105 pg/mL (range: 82-127 pg/mL).
- In all cases, ultrasound (USG) revealed a solitary primary parathyroid lesion (PPL).

There was an indication for surgery for PPL in patients with HP. All patients underwent PS imaging with Tc-99m sestamibi. For parathyroid scintigraphy (PS), patients received 16-18 mCi of intravenous Tc-99m sestamibi. Images were obtained at the 20th (early) and 120th (late) minutes (3). Scintigraphic images were performed on a Siemens E-cam double-headed gamma camera with a high-resolution parallel hole collimator in a 128x128 matrix. A thyroid scintigraphy examination was performed with Tc-99m pertechnetate on a separate day (Figure 1-2). MIS with IGP was planned for the patients. In the intraoperative gamma probe method, a crystal probe was used, and in vivo lesion/neck, lesion/thyroid counts, and lesion/operational area counts were measured after the lesion was removed. In vivo, when the parathyroid lesion/thyroid gland count ratio was ≥ 1.5 , and the parathyroid lesion/background activity was ≥ 2.5 , and if the parathyroid lesion/background activity at the operation site was $\geq 20\%$ after the pathological gland was removed, it was considered compatible with parathyroid adenoma. At the end of the operation, it was observed that the counts were equalized in all four quadrants.

Figure 1: In primary parathyroid lesion (parathyroid adenoma) located in the right inferior localization; A. 20. min (early) B. 120. min (late) radionuclide imaging C. Thyroid Scintigraphy. There is delayed accumulation in the primary parathyroid lesion.

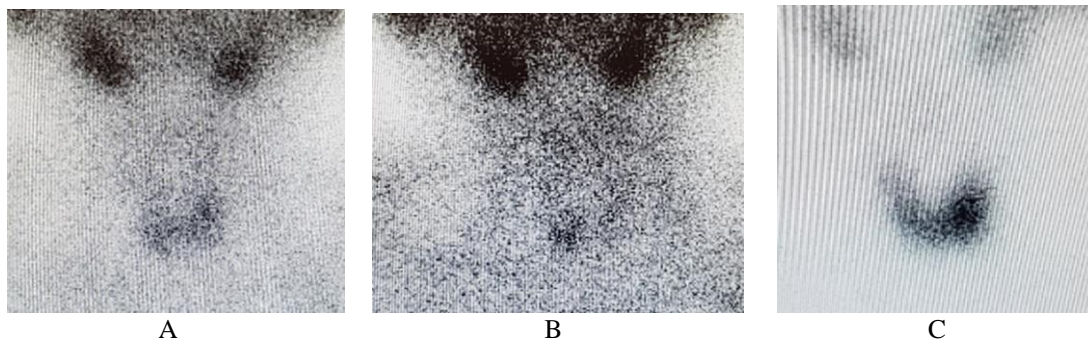
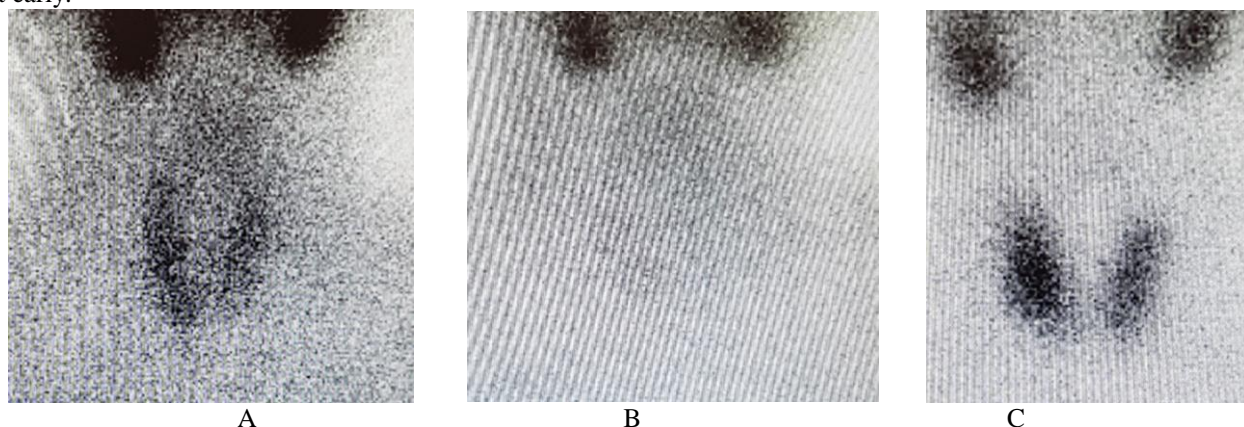


Figure 2: The patient with a primary parathyroid lesion (parathyroid adenoma) in the right inferior A: 20. min (early) B: 120. min (late) radionuclide imaging C: Thyroid Scintigraphy. The activity in the primary parathyroid lesion was washed out early.



The primary parathyroid lesion that was removed was sent to pathology. Our retrospective study was approved by Gaziosmanpaşa Training and Research Hospital Ethics Committee with 340 numbers on 22.09.2021.

Statistics: SPSS version 21 software was used for statistical analysis. Variables were expressed as the number and percentage of cases for categorical variables and the median (minimum-maximum) for continuous variables. The Mann-Witney U test was used for non-normally distributed continuous variables, and the Chi-square test was used for categorical variables. $p < 0.05$ was accepted as statistically significant.

RESULTS

In 27 patients (56.3%), PPL was visualized in the same localization as USG of the neck in PS imaging. However, in 21 (43.8%) patients, the lesion observed in the 20th-minute images was washed out at the same rate as the thyroid tissue in the 120th-minute late images. Surgery was planned as minimally invasive surgery (MIS) with an intraoperative gamma probe (IGP) in all patients. However, in 6 patients, the operation was expanded and four glands were explored (**Figure 3**). All excised lesions were reported to be consistent with parathyroid adenoma in both the frozen and pathological paraffin sections. Only one lesion from each patient was excised. In the follow-ups, the PTH values were normalized in the patients after the operation. In two of the 6 patients in whom the operation had to be expanded, the lesion was localized pre-operatively with late accumulation in PS. Early wash-out was observed in 4 patients. All six of these patients were diagnosed with multinodular goiter (MNG). The results are summarized in **Tables 1 and 2**, as well as **Figure 3**.

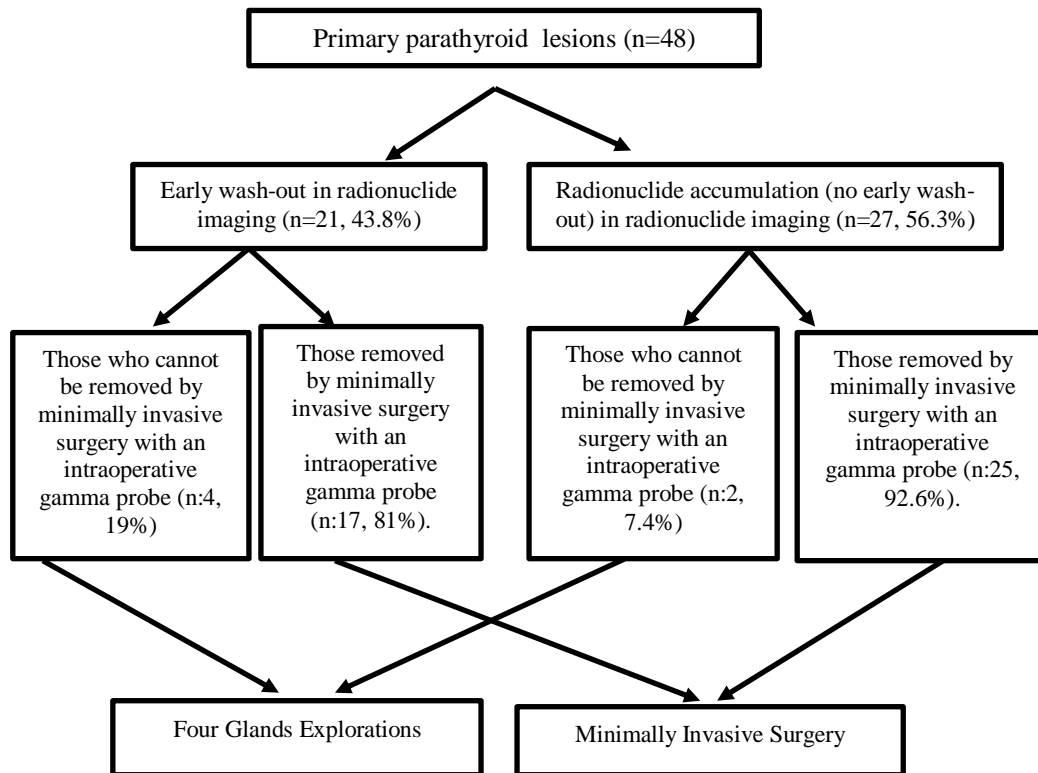


Figure 3: Schematic representation of data of our patients with Primary Parathyroid Lesions

Table 1: Data on primary parathyroid lesions with early wash-out and late accumulation on radionuclide imaging.

	Early wash-out (n:21)	Late accumulation (n:27)	p
age	44 (37-51)	45 (38-50)	0.875
Gender (male/female)(In gender%)	13/8 (43.3%/44.4%)	17/10	
Parathormone (pg/mL)	98 (82-127)	108 (87-127)	0.289
Presence of Multinodular goiter (+/-)	9/12 (42.9%/ 44.4%)	12/15 (57.1%/ 55.6%)	0.912
Minimally invasive surgery (+/-)	4/17 (66.7%/40.5%)	2/25 (33.3%/59.5%)	0.383
Four gland exploration (+/-)	17/4 (40.5%/66.3%)	25/2 (59.5%/33.3%)	0.383

Table 2: Data on lesions that were extracted with minimally invasive surgery with intraoperative gamma-probe and those that could not be extracted

	Primary parathyroid lesions that cannot be removed by minimally invasive surgery (n:6)	Primary parathyroid lesions removed by minimally invasive surgery (n:42)	p
Gender (female/male)	4/2 (13.3%)/11.1%)	26/16 (86.7%/88.9%)	1
AQge	41.3 (37-45)	44 (37-51)	0.354
Multinodular goiter (-/+)	0/6 (0 %/ 22.2%)	21/21 (100%/77.8%)	0.029
Parathyroid hormone (pg/mL)	109.5 (88-127)	106.5 (82-127)	0.543

DISCUSSION

Determining the localization of the pathological lesion with preoperative localization methods enables minimally invasive procedures and increases the surgical success rate. Both four-gland exploration and MIS aim to remove the pathological lesion while preserving the normally functioning glands. It is aimed to keep repetitive neck operations and postoperative complications such as adhesions at a minimal level. Although the removal of multiple glands creates more curative results, it is not preferred (5). In cases where a preoperative focus was determined with the help of PS and USG, unilateral exploration for the ipsilaterally located gland may be recommended first, when no lesion is found with MIS.

Without a pathological focus in ipsilateral exploration, four gland explorations can be performed (6). Surgery may be indicated in the presence of PPL with HP. These situations can be summarized as follows: high serum calcium, low bone mineral density, associated fracture formation, kidney stones, and kidney failure (7). In 21 of our 48 cases, the PPL image that became focal in the early images of PS disappeared in the late images. However, MIS with IGP was still possible in 17 patients. More counts were obtained with IGP compared to the surrounding tissue. The lesion was found by four gland explorations in 4 patients. All of these four patients had multiple nodules in the thyroid gland.

Four gland exploration was performed in 2 of 27 patients with late accumulation. In minimally invasive surgery (MIS) accompanied by intraoperative gamma probe (IGP), the presence of multiple nodules in the thyroid gland can pose challenges in localizing solitary primary parathyroid lesions (PPL). Sestamibi is a lipophilic cation that accumulates in the mitochondria inside the cell (8). In PPL, an excess of vascularity and mitochondria-rich oxyphilic cells accumulate sestamibi (8). In addition, the release of accumulated sestamibi from the PPL is slow compared to the surrounding thyroid tissue and normal parathyroid glands (9). The sensitivity of 99m Tc-sestamibi in localizing the lesion in cases with a solitary adenoma has been reported as 54%-96% (10,11). In cases with a solitary adenoma, the specificity of scintigraphy in localizing the adenoma has been reported to be 83% to 96% (12,13). SPECT (tomographic) images effectively reveal PPLs located posterior to the thyroid gland (14). Both planar and SPECT imaging were conducted on the patients in our study. The mean time to reach the adenoma after the skin incision has been reported as 14 minutes (15). In our study, the time to reach the adenoma was also similar. Our 27 patients had multinodular goiter (MNG) in the thyroid. Half of the 42 patients who could have PPL removed with IGP-guided MIS had MNG. All 6 patients in whom PPL could not be removed by MIS accompanied by IGP had a diagnosis of MNG. MNG diagnosis decreased the success of MIS, especially in lesions with early wash-out. Early wash-out was observed in 4 of 6 cases in which MIS failed. With IGP, a count of more than 20% can be obtained in thyroid nodules and hyperplasia. This may cause false positivity intraoperatively (16-17). It has been reported that the time required to reach the highest adenoma/background activity can vary from patient to patient (18). PPL on USG; It is seen as a hypoechoic, homogeneous, well-circumscribed mass. Thus, it is separated from the surrounding hyperechoic thyroid gland (19). USG only gives size information and not about function. The lesion within the thyroid may also be a thyroid adenoma. Success increases when USG and scintigraphy are used together (20). Normal glands cannot be visualized with MRI. In a study comparing MR and scintigraphy, the sensitivity of PS was 86%, and the sensitivity of MR was 71% in localizing PPL (21). Thyroid adenomas, carcinoma, and inflammatory thyroid diseases accumulate sestamibi. Sestamibi may undergo delayed release in these lesions as in parathyroid adenomas. Inflammatory or malignant cervical lymphadenopathies may cause false positivity (3).

Study Limitations: The weakness of our study is that it is retrospective.

CONCLUSION

In cases with PH and solitary PPL, it is aimed to remove the pathological lesion with MIS and to leave the glands that continue their normal function in place. Preoperative localization methods help the surgeon in this regard, but pathologies in the surrounding tissue may reduce the success of MIS.

Abbreviations:

USG: Ultrasonography

PTH: Parathormone

IGP: Intraoperative Gamma-Probe

PPL: Primary Parathyroid Lesion

MIS: Minimally Invasive Surgery

PS: Parathyroid Scintigraphy

MNG: Multinodular Goiter

Acknowledgements: None

Conflict of interest: The authors declared no potential conflicts of interest with respect to the research, authorship, and/or publication of this article.

Author Contributions: **SC;** contributed to the conception of the work, execution of the study, revision of the draft, approval of the final manuscript version, and concur with all aspects of the work. All authors have reviewed the manuscript, and affirm that they fulfill the ICMJE criteria for authorship.

Ethical approval: All procedures followed were in accordance with the ethical standards of the responsible committee on human experimentation (institutional and national) and/or with the Helsinki Declaration of 1964 and later versions. Our retrospective study was approved by Gaziosmanpaşa Training and Research Hospital Ethics Committee with 340 numbers on 22.09.2021.

REFERENCES

- Garimella V, Yeluri S, Alabi A, Samy AK. Minimally invasive video-assisted parathyroidectomy is a safe procedure to treat primary hyperparathyroidism. *The Surgeon IO*, 2012; 202-205.
- Sullivan DP, Scharf SC, Komisar A. Intraoperative Gamma Probe Localization of Parathyroid Adenomas. *The Laryngoscope* 111, 2001; 912-917
- Varoğlu E, Bayraktar R, Argon M, Atasever T, Çelen YZ. Parathyroid Scintigraphy Application Guideline. *Turk J Nucl Med* 2001; 10(Suppl.): 35-9.
- Denham DW, Norman J. Cost-effectiveness of preoperative sestamibi scan for primary hyperparathyroidism is dependent solely upon the surgeon's choice of operative procedure. *Journal American College of Surgery* 1998 186; 293-305
- Norman J, Politz D. Prospective Study in 3000 Consecutive Parathyroid Operations Demonstrates 18 Objective Factors that Influence the Decision for Unilateral versus Bilateral Approach. *American College of Surgeons* 211 (2), 2010; 244-249
- Goldstein RE, Blevins L, Delbeke D, Martin WH. Effect of Minimally Invasive Radioguided Parathyroidectomy on Efficacy, Length of Stay, and Costs in the Management of Primary Hyperparathyroidism. *Annals of Surgery* 231(5), 2000; 732-742.
- Bilezikian JP, Khan AA, Silverberg SJ, et al. Evaluation and Management of Primary Hyperparathyroidism: Summary Statement and Guidelines from the Fifth International Workshop. *J Bone Miner Res* 2022; 37(11): 2293-314.
- Melloul M, Paz A, Koren R, 99mTc-MIBI scintigraphy of parathyroid adenomas and its relation to tumor size and oxyphil cell abundance. *European Journal of Nuclear Medicine* 2001; 28 (2):209-213
- Falke THM, Sandler MP, Schipper J. Parathyroid glands. In: Sandler MP, Coleman RE, editors: *Diagnostic Nuclear Medicine*. 3rd edition. Baltimore (MD): Williams & Wilkins; 1994.p.991-1012

10. Civelek AC, Ozalp E, Donovan P. Prospective evaluation of delayed technetium-99m sestamibi SPECT scintigraphy for preoperative localization of primary hyperparathyroidism. *Surgery* 2002; 131(12):149-157.
11. Moka D, Voth E, Dietlein M, et al. Technetium 99m-MIBI-SPECT: a highly sensitive diagnostic tool for localization of parathyroid adenomas. *Surgery* 2000; 128(1): 29-35
12. Lavelly WC, Goetze S, Friedman KP, et al. Comparison of SPECT/CT, SPECT and planar imaging with single and dual-phase 99m Tc-sestamibi scintigraphy. *Journal of Nuclear Medicine* 2007; 48(7):1084-1089
13. Ruda Jm, Hollanbeak CS, Stack BC Jr. A systematic review of the diagnosis and treatment of primary hyperparathyroidism from 1995 to 2003. *Otolaryngol Head Neck Surg* 2005; 132(3): 359-372
14. Sharma J, Mazzaglia P, Milas M, et al. Radionuclide imaging for hyperparathyroidism (HPT); which is the best technetium 99m-sestamibi modality? *Surgery* 2006; 140(6):856-863
15. Harris L, Yoo J, Driedger A, et al. Accuracy of technetium-99m SPECT-CT hybrid images in predicting the precise intraoperative anatomical location of parathyroid adenomas. *Head Neck* 2008; 30(4): 509-517
16. Rubello D, Giannini S, Martini C, et al. Minimally invasive radio-guided parathyroidectomy. *Biomed Pharmacother* 2006;60(3):134-148
17. Rubello D, Pelizzo MR, Boni G, et al. Radioguided surgery of primary hyperparathyroidism using the low-dose 99mTc-sestamibi protocol: multiinstitutional Imaging of Parathyroid Glands 413 experience from the Italian Study Group on Radioguided Surgery and Immunoscintigraphy (GISCRIS). *J Nucl Med* 2005;46(2):220-226.
18. Bozkurt MF, Ugur O, Hamaloglu E, et al. Optimization of the gamma probe-guided parathyroidectomy. *Am Surg* 2003;69(8):720-725
19. Tublin ME, Pryma DA, Yim JH, et al. Localization of parathyroid adenomas by sonography and technetium tc 99m sestamibi single-photon emission computed tomography before minimally invasive parathyroidectomy: are both studies really needed? *J Ultrasound Med* 2009;28(2):183-190
20. Sukan A, Reyhan M, Aydin M, et al. Preoperative evaluation of hyperparathyroidism: the role of dual-phase parathyroid scintigraphy and ultrasound imaging. *Ann Nucl Med* 2008;22(2):123-131.
21. Ruf J, Lopez HE, Steinmuller T, et al. Preoperative localization of parathyroid glands. Use of MRI, scintigraphy, and image fusion. *Nuklearmedizin* 2004; 43(3):85-90

Copyright © 2023 The Author(s); This is an open-access article distributed under the terms of the Creative Commons Attribution License (<http://creativecommons.org/licenses/by/4.0>), (CC BY NC) which permits unrestricted use, distribution, and reproduction in any medium, provided the original work is properly cited. *International Journal of Medical Science and Discovery*.