

Peripapillary Microvasculature in Branch Retinal Vein Occlusion (BRVO) Treated With Anti-VEGF: An OCTA Study

Emine Çiloğlu^{1*}

Abstract

Objective: Aim of this study is to evaluate the changes in peripapillary vessel density (VD) and peripapillary nerve fiber layer thickness (PPRNFL) after intravitreal anti-VEGF injections in patients with Branch Retinal Vein Occlusion (BRVO) with macular edema.

Material and Methods: Sixty eyes of 30 patients with unilateral macular edema due to BRVO who underwent 3 dose loading anti-VEGF treatments were included in the study. The peripapillary capillary vessel density (RPCVD) and PPRNFL were evaluated with optical coherence tomography angiography (OCTA). The measurements were done before and at least one month after a loading dose of anti-VEGF. The measurements of BRVO eyes before treatment were compared with the healthy fellow eyes and the values measured after treatment.

Results: There was a statistical difference between the pre-injection and post-injection periods at the inside disc and peripapillary VD parameters ($p < 0.001$, $p = 0.01$, respectively). Compared with the fellow eyes of the patients, the vessel density in the eyes with BRVO was significantly lower in the whole image, inside the disc, and peripapillary area. ($p = 0.015$, $p = 0.020$, $p = 0.027$, respectively). There was no significant change in PPRNFL values before and after injections. When eyes with BRVO were compared with healthy eyes, eyes with BRVO showed reduced PPRNFL values initially but that was not statistically significant.

Conclusion: Inside disc and peripapillary VD values were increased after injection. Even though anti-VEGF agents may contribute to neurodegeneration, we think that this increase in perfusion prevents possible neurodegeneration.

Key Words: branch retinal vein occlusion, optical coherence tomography angiography, peripapillary retinal nerve fiber layer, peripapillary capillary vessel density

Introduction

Branch retinal vein occlusion (BRVO) is a relatively common retinal vascular occlusive disease that can cause loss of vision in elderly individuals. The most common cause of visual impairment in eyes with BRVO is macular edema. Laser photocoagulation, intravitreal vascular endothelial growth factor inhibitors (anti-VEGF) or steroid injections are used to treat macular edema. Repeated anti-VEGF injections could be required due to recurrent macular edema.

Recently, optical coherence tomography angiography (OCTA) has begun to be used as a new and noninvasive method for high-resolution visualization of the microvascular structure of the retina and choroid. It allows the quantitative evaluation of perfusion in the optic nerve head, peripapillary, and macular areas. (1)

In studies with OCTA, changes in microcirculation have been shown to be associated with the development of macular edema, and it was shown that parafoveal vessel density in both superficial and deep capillary plexus had been reduced. Also, it was shown that retinal nonperfused areas were decreased with anti-VEGF treatment and retinal blood flow, especially in deep plexus was increased. (2-4)

Peripapillary vessel density (VD) is an in-depth study of glaucoma and diabetic retinopathy. (5) Numerous studies have shown a decrease in vessel density quantitatively after glaucomatous damage. (6,7)

This study aimed to evaluate the changes in peripapillary VD and PPRNFL thickness after intravitreal anti-VEGF injections in patients with BRVO with macular edema.



Material and Method

Our study is a retrospective study, and records of patients who had received three loading doses of anti-VEGF therapy in three months for macular edema due to BRVO were evaluated. Ethics committee approval was obtained for the study and all procedures were performed in accordance with the Helsinki Declaration.

All patients underwent a complete ophthalmologic examination. The best corrected visual acuity (Snellen), intraocular pressure measurement with Goldmann applanation, anterior segment and fundus evaluation by biomicroscopic examination and OCTA were performed. The inclusion criteria of the patients were; the presence of macular edema due to BRVO, over 40 years of age, no previous injection or laser application. Exclusion criteria were; the presence of diabetes mellitus, age-related macular degeneration, vitreous hemorrhage, high myopia (>-6 diopters), glaucoma, uveitis, ocular trauma, poor quality of OCTA measurements, significant media opacities and lack of control examination.

OCTA (Optovue RTVue XR Avanti; Optovue Inc., Fremont, California) was used for assessment of macular retinal vascularization. AngioVue uses the split-spectrum amplitude-decorrelation angiography (SS-ADA) algorithm to detect erythrocyte movements. Advantage of this software, it makes it possible to visualize the vascularization of choroid and retina noninvasively via motion contrast.

The 4.5 x 4.5-mm scanning area of peripapillary images were centered on the optic disc. Activation of the eye-tracking function was done. Motion correction to minimize motion artifacts arising from micro saccades and fixation changes was applied. The peripapillary capillary vessel density (RPCVD) was measured at a 1.00-mm-wide elliptical annulus extending outward from the optic disc boundary in the radial peripapillary capillary (RPC) zone. The RPC layer extends from the internal limiting membrane to the nerve fiber layer (NFL).

The capillary VD percentages were automatically calculated as the proportion of the area with flowing blood vessels, defined by pixels with decorrelation values above the SS-ADA threshold level. The software version we used provides separate information on peripapillary capillary VD (only information arriving from the RPC layer capillaries is analyzed). For analyses, VD is automatically calculated for the whole image, inside-disc area, and the peripapillary area, respectively.

The PPRNFL thickness was also measured using the AngioVue (Optovue, Inc.). The PPRNFL thickness was assessed at a 3.45-mm-diameter circle around the optic disc in the ONH mode (Figure 1). Image quality was assessed for all OCTA scans. Poor quality images were defined as scans with quality index <6 or images with residual motion artifacts, segmentation errors were excluded from the analysis. Poor-quality OCTA images were characterized by doubling of vessel images and artifact lines in the target area.

The treatment regimen started with three monthly injections. After this loading phase, the injections were continued in the presence of macular edema. The measurements were done before and at least one month after a loading dose of anti-VEGF. The measurements of BRVO eyes before treatment were compared with the healthy fellow eyes and the values measured after treatment. Statistical analysis of the study was performed using the SPSS 20.0 (IBM Inc., Chicago, IL, USA) program. The Kolmogorov-Smirnov test was used to assess the appropriateness of calculations to normal distribution. In parametric comparisons, the Student t-test was used for two independent groups. Mann-Whitney U test was used for variables with no normal distribution. A 5% level of significance was adopted; therefore, results with a p-value <0.05 were considered significant.

Results

Sixty eyes of 30 patients with unilateral macular edema due to BRVO who underwent 3 dose loading anti-VEGF treatments were included in the study. The mean age of the patients was 58.12 ± 11.05 years. Mean visual acuity (Snellen) was 0.2 at baseline, 0.5 after first injection, and 0.7 after 3 doses of anti-VEGF treatment. ($P < 0.001$)

In the whole image analysis, RPCVD (%) did not differ before and after injection. There was a statistical difference between the pre-injection and post-injection periods at the inside disc and peripapillary VD parameters ($p < 0.001$, $p = 0.01$, respectively). Compared with the fellow eyes of the patients, the vessel density in the eyes with BRVO was significantly lower in the whole image image, inside disc, and peripapillary area. ($p = 0.015$, $p = 0.020$, $p = 0.027$, respectively)

There was no significant change in PPRNFL values before and after injections. When eyes with BRVO were compared with healthy eyes, eyes with BRVO showed reduced PPRNFL values initially but that was not statistically significant.

Table 1: Comparison of OCTA parameters between the BRVO eyes and the fellow eyes

	BRVO	Fellow eyes	P value
RPCVD (%)			
Whole image	48.8±3.15	54.8±2.39	0.015*
Inside disc	47.3±2.24	54.9±3.54	0.020*
Peripapillary	49.2±2.14	53.8±2.58	0.027*
PPRNFL (µm)			
Mean	108.54±8.11	114.36±7.80	0.056
Superior	109.55±9.41	114.72±8.38	0.060
Inferior	107.75±9.22	113.53±8.24	0.055

RPCVD: radial peripapillary capillary vessel density, PPRNFL: Peripapillary retinal nerve fiber layer

Table 2: The OCTA parameters in patients with BRVO after treatment

BRVO	Before treatment	After Treatment	P value
RPCVD (%)			
Whole image	48.8±3.15	49.5±2.82	0.082
Inside disc	47.3±2.24	50.4±2.43	<0.001*
Peripapillary	49.2±2.14	52.8±2.26	0.01*
PPRNFL (µm)			
Mean	108.54±8.11	107.15±8.12	0.850
Superior	109.55±9.41	109.24±8.21	0.650
Inferior	107.75±9.22	106.45±7.86	0.760

RPCVD: radial peripapillary capillary vessel density, PPRNFL: Peripapillary retinal nerve fiber layer

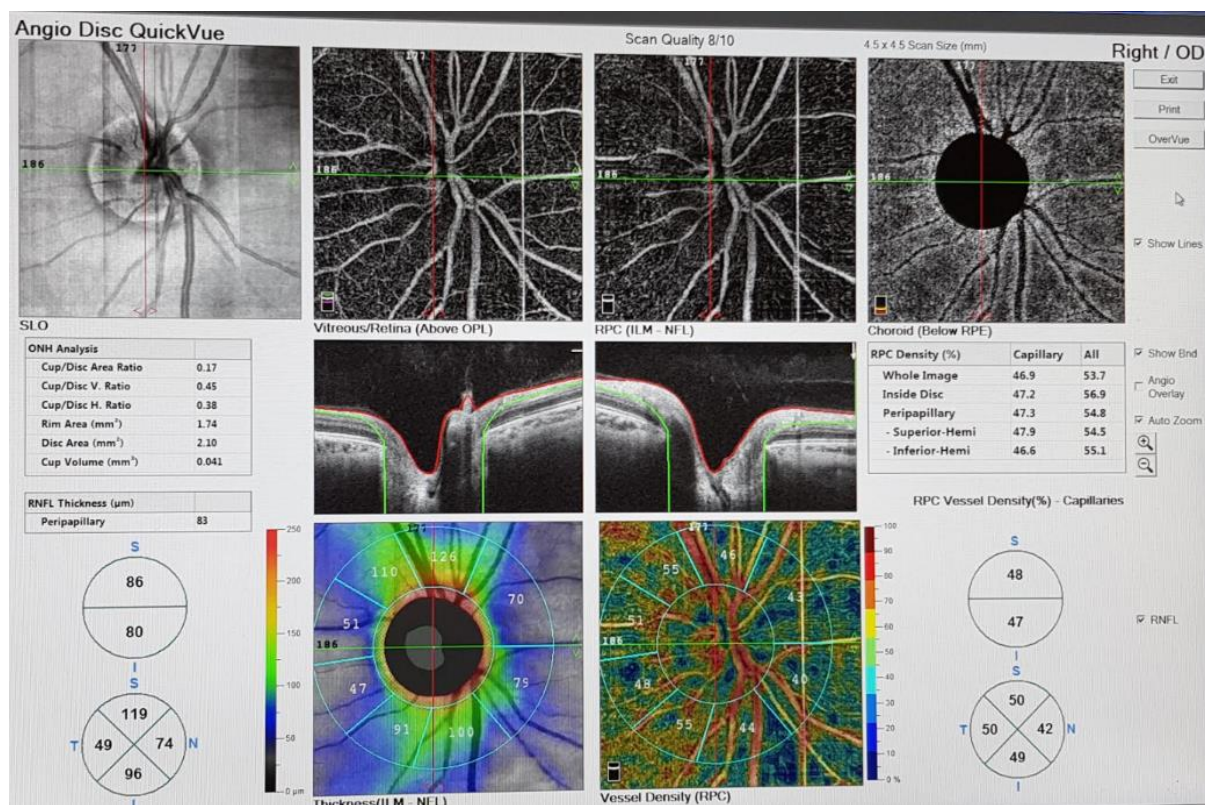


Figure 1: The OCTA image. At the left side peripapillary nerve fiber layer thickness analysis, at the right side the peripapillary capillary vessel density analysis.

Discussion

In this study, we studied peripapillary microvascular changes in patients with BRVO who undergone intravitreal anti-VEGF injections due to macular edema.

There are several studies evaluating OCTA features in RVO. (8,9) FAZ enlargement, capillary dropouts, reduction of VD in the superficial (SCP) and deep capillary plexus (DCP) have been reported. Samara et al. investigated the vascular density of the SCP and DCP in the eyes with BRVO and reported a decrease in vascular densities both in the SCP and DCP with the correlation between FAZ, VD and visual acuity. (10) OCTA may be useful for evaluating microvascular changes before an occlusive event, Adhi et al. showed how the eyes of RVO patients present decreased vascular perfusion of DCP compared to healthy controls. (11)

In this study, when compared with the unaffected eyes of the patients before treatment, it was found that the PPRNFL thickness was significantly thinner, and the whole image, inside the disc and peripapillary VD was decreased in BRVO eyes than the other fellow eyes.

Macular edema is the most common cause of decreased visual acuity in patients with BRVO. Macular edema results from the release of substances that enhance vascular permeability, such as VEGF produced in the retina, due to the disruption of the tight junctions between endothelial cells and adhesions between the vitreous and retina and the disruption of the blood-retinal barrier. (12) Recently, anti-VEGF drugs have been used frequently in the treatment of macular edema due to BRVO.

It was demonstrated that a slight decrease in average macular vessel density, despite the resolution of macular edema, in patients with RVO with macular edema treated with intravitreal anti-VEGF or dexamethasone injections. (13,14) In this study, we evaluated the vessel density of inside disc and peripapillary region in BRVO patients. We found a significant difference in the vessel density of inside disc and peripapillary region before and after treatment in BRVO eyes.

Campochiaro et al. showed that an aggressive blocking of VEGF might reduce but not prevent the progression of retinal nonperfusion(4). Monthly anti-VEGF injections may potentially improve outcomes due to a secondary reduction in the progression of ischemia demonstrated by Mir et al (15).

It is clear that VEGF has not only angiogenic effects but also direct effects on neuronal cells as neuroprotective. Reduced VEGF levels are thought to play a role in neurodegenerative diseases (16).

Many studies have evaluated RNFL thickness after intravitreal ranibizumab injections. Some of these studies reported a decrease in RNFL thickness, while others showed no detectable changes (17-19).

Shin et al. evaluated changes in peripapillary microvascular parameters in the other eyes of patients with unilateral BRVO and reported that peripapillary VD and perfusion density were decreased compared to the control group and RNFL thinning were significant in the average, inferior and temporal quadrants. (20) In our study, peripapillary RNFL was thinner in BRVO eyes than fellow healthy eyes. There was no significant difference in the RNFL values between before and after intravitreal injections. Intravitreal injections of ranibizumab, bevacizumab, or aflibercept reduce only one VEGF subtype, and the other VEGF isoforms may protect the RNFL. Furthermore, the effect of the anti-VEGF monoclonal antibodies is transient, requiring monthly re-injections.

Moghimi et al. reported that the VD of macular and optic nerve head using OCTA is associated with the rate of RNFL loss and should be considered when evaluating the risk for glaucoma progression. (21) Blood flow to the RNFL is supplied by the microcirculation from the retinal RPCs. RPCs are difficult to observe with conventional FFA. OCTA helps to evaluate optic nerve head perfusion.

Conclusion

In BRVO patients, when we compared peripapillary RNFL with the unaffected eye, in BRVO eyes the RNFL were thinner. We did not find any difference between RNFL values before and after intravitreal injection. Inside disc and peripapillary VD values were increased after injection. Even though anti-VEGF agents may contribute to neurodegeneration, we think that this increase in perfusion prevents possible neurodegeneration.

Conflict of Interest: No potential conflict of interest was reported by the author.

Acknowledgement: None

Conflict of interest statement: The authors declare that there is no actual or potential conflict of interest.

Author's contributions: EC; Design of research, data collection and Patient examinations, EC; preparation of article and revisions

Ethical issues: Author declare, originality and ethical approval of research. The study was conducted under defined rules by the Local Ethics Commission guidelines and audits.

References

1. Tan ACS, Tan GS, Denniston AK, Keane PA, Ang M, Milea D, et al. An overview of the Clinical Applications of Optical Coherence Tomography Angiography. *Eye* 2018;32:262-286.
2. Kang JW, Yoo R, Jo YH, Kim HC. Correlation of microvascular Structures on Optical Coherence Tomography Angiography with Visual Acuity in Retinal Vein Occlusion. *Retina* 2017;37:1700-1709.
3. Suzuki N, Hirano Y, Tomiyasu T, Esaki Y, Uemura A, Yasukawa T, et al. Retinal Hemodynamics Seen on Optical Coherence Tomography Angiography before and after treatment of Retinal Vein Occlusion. *Invest Ophthalmol Vis Sci*. 2016;57:5681-5687.
4. Campochiaro PA, Bhisitkul RB, Shapiro H, Rubio RG. Vascular Endothelial Growth Factor Promotes Progressive Retinal Nonperfusion in Patients with Retinal Vein Occlusion. *Ophthalmology* 2013;120:795-802.
5. Liu L, Wang Y, Liu HX, Gao J. Peripapillary Region Perfusion and Retinal Nerve Fiber Layer Thickness Abnormalities in Diabetic Retinopathy Assessed by OCT Angiography. *Trans Vis Sci Technol* 2019;8:14.
6. Wang X, Jiang C, Kong X, Yu x, Sun X. Peripapillary Retinal Vessel Density in Eyes with Acute Primary Angle Closure: An Optical Coherence Tomography Angiography Study. *Graefes Arch Exp Ophthalmol*. 2017;255:1013-1018.
7. Kim SB, Lee EJ, Han JC, Kee C. Comparison of peripapillary vessel density between preperimetric and perimetric glaucoma evaluated by OCT-Angiography. *Plos ONE* 2017;12:e0184297.
8. Coscas F, Glacet-Bernard A, Miere A, Caillaux V, Uzzan J, Lupidi M, et al. Optical Coherence Tomography Angiography in Retinal Vein Occlusion: Evaluation of Superficial and Deep Capillary Plexa. *Am J Ophthalmol* 2016;161:160-171.
9. Seknazi D, Coscas F, Sellam A, Rouimi F, Coscas G, Souied EH, et al. Optical Coherence Tomography Angiography in Retinal Vein Occlusion: Correlations between macular vascular density, visual acuity, and peripheral nonperfusion area on fluorescein angiography. *Retina* 2018;38:1562-1570.
10. Samara W.A, Shahlaee A, Sridhar J, Khan MA, Ho AC, Hsu J. Quantitative Optical Coherence Tomography Angiography Features and Visual Function in Eyes with Branch retinal vein occlusion. *Am J Ophthalmol*. 2016;166:76-83.
11. Adhi M, Bonin Filho MA, Louzada RN, Kuehlewein L, De Carlo TE, Bauman CR, et al. Retinal Capillary Network and Foveal Avascular Zone in Eyes with Vein Occlusion and Fellow Eyes Analyzed with Optical Coherence Tomography Angiography. *Invest Ophthalmol Vis Sci* 2016;59:486-494.
12. Rehak J, Rehak M. Branch retinal vein occlusion: pathogenesis, visual prognosis, and treatment modalities. *Curr Eye Res*. 2008;33:111-31.

13. Sellam A, Glacet-Bernard A, Coscas F, Miere A, Coscas G, Souied E. Qualitative And Quantitative Follow-up Using Optical Coherence Tomography Angiography Of Retinal Vein Occlusion Treated With Anti-VEGF: Optical Coherence Tomography Angiography Follow-up of Retinal Vein Occlusion. *Retina*. 2017 Jun;37(6):1176-84.
14. Glacet-Bernard A, Sellam A, Coscas F, Coscas G, Souied EH. Optical Coherence tomography angiography in retinal vein occlusion treated with dexamethasone implant: a new test for follow-up evaluation. *Eur J Ophthalmol*. 2016; 26:460-8.
15. Mir TA, Kherani S, Hafiz G, Scott AW, Zimmer-Galler I, Wenick AS, et al. Changes in retinal nonperfusion associated with suppression of vascular endothelial growth factor in retinal vein occlusion. *Ophthalmology*. 2016;123:625-34.
16. Sondell M, Lundborg G, Kanje M. Vascular endothelial growth factor has neurotrophic activity and stimulates axonal outgrowth, enhancing cell survival and Schwann cell proliferation in the peripheral nervous system. *J Neurosci* 1999 Jul 15;19(14):5731–5740
17. Demirel S, Batioğlu F, Özmert E, Erenler F. The effect of multiple injections of ranibizumab on retinal nerve fiber layer thickness in patients with age-related macular degeneration. *Curr Eye Res* 2015 Jan;40(1):87–92.
18. Martinez-de-la-Casa JM, Ruiz-Calvo A, Saenz-Frances F, Reche-Frutos J, Calvo-Gonzalez C, Donate-Lopez J, et al. Retinal nerve fiber layer thickness changes in patients with age-related macular degeneration treated with intravitreal ranibizumab. *Invest Ophthalmol Vis Sci* 2012 Sep 4;53(10):6214–6218.
19. Horsley MB, Mandava N, Maycotte MA, Kahook MY. Retinal nerve fiber layer thickness in patients receiving chronic anti-vascular endothelial growth factor therapy. *Am J Ophthalmol* 2010 Oct;150(4):558–561.
20. Shin Y, Nam KY, Lee SE, Lim HB, Lee MW, Jo YJ, et al. Changes in peripapillary microvasculature and retinal thickness in the fellow eyes of patients with unilateral retinal vein occlusion: An OCTA study. *Invest Ophthalmol Vis Sci* 2019;60:823-829.
21. Moghimi S, Zangwill LM, Pentead RC, Hasenstab K, Ghahari E, Hou H, et al. Macular and optic nerve head vessel density and progressive retinal nerve fiber layer loss in glaucoma. *Ophthalmology* 2018;125:1720-1728.