

## The treatment of chronic wounds with boric acid polyurethane sponges combined with negative pressure wound treatment: a multi-center, prospective, randomized study

Ahmet Kapukaya<sup>1</sup>, Evren Karaali<sup>1\*</sup>, Tayyibe Saler<sup>2</sup>, Ersin Fidan<sup>1</sup>, İsmail Akçay<sup>1</sup>, Asena Ayça Özdemir<sup>3</sup>, Orhan Büyükbekci<sup>4</sup>, Barış Sarı<sup>1</sup>, Abuzer Uludağ<sup>5</sup>, Özgür Külahçı<sup>6</sup>, Mehmet Bankır<sup>2</sup>

### Abstract

**Objective:** This study aimed to compare the outcomes of the use of polyurethane boric acid sponges and sponges containing silver nitrate over the negative pressure wound treatment.

**Materials and methods:** The patients were separated as Group 1 (n:30) treated with boric acid group, and Group 2 (n:34) treated with silver nitrate group (Group 2). The wound healing of each patient was evaluated quantitatively on a cellular basis from a table of macroscopic and histopathological scoring.

**Results:** No statistically significant difference was determined between the groups applied with boric acid and silver nitrate in respect of the culture results from the first visit (p:0.705). In the final evaluation of wound dimensions on day 21, a significant reduction was seen in wound width (p=0.001), wound length (p=0.003), and wound depth (p<0.001) in the boric acid group, and no significant results were obtained in the silver nitrate group. In the quantitative cellular evaluations, a statistically significant difference was determined in favor of the boric acid group in respect of inflammatory cell count, angiogenesis, granulation, and re-epithelialization (p<0.001 for all).

**Conclusion:** Sponges with boric acid can have a positive effect on chronic wound recovery by improving cellular proliferation, cellular differentiation and cellular migration in addition to antimicrobial properties when used in combination with the negative pressure wound treatment system. Therefore, boric acid sponges seem to be a good alternative to silver nitrate sponges.

**Keywords:** chronic wounds, boric acid, negative pressure treatment

### Introduction

The healing of chronic wounds tends to not advance beyond the inflammatory stage (1). For the wound to emerge from that stage and enter the healing period, the infection must be brought under control, angiogenesis must be provided and the epithelialization phase should be accelerated. Many methods and technological products are used to reach these goals in the treatment of chronic wounds. One of the most important of these is the vacuum-assisted wound closure (VAC) system, also known as negative pressure wound treatment (NPWT). However, the debate continues about the optimum physicochemical structure of the interface contact material in this system.

Silver nitrate polyurethane sponges are currently used as wound interface material. The most important property of these sponges is the broad spectrum anti-bacterial effect. However, local and systemic complications of this substance, which are not dose-dependent, have raised concerns in clinicians (2-4). Boric acid has long been used in topical wound treatments, such as eye and ear drops, and in recent years, promising results have been obtained from in vitro and in vivo studies of infected wounds (5-7). In addition to the valuable anti-microbial effect of boric acid against yeast and fungi, it also has the effect of increasing cellular proliferation, macrophage migration, and levels of growth factor and dermal cell gene expression.

Received 20-11-2020 Accepted 14-12-2020 Available Online 18-12-2020 Published 30-12-2020

1 University of Health Science Adana City Training and Research Hospital, Dept of Orthopedics and Traumatology, Adana, TR

2 University of Health Science Adana City Training and Research Hospital, Dept of Internal Medicine, Adana, TR

3 Mersin University, School of Medicine, Medical Education Dept, Mersin, TR

4 Gaziantep University Şahinbey Training and Research Hospital, Department of Orthopedics and Traumatology, Gaziantep, TR

5 Adiyaman University, Faculty of Medicine, Dept of Orthopedics and Traumatology, Adiyaman, TR

6 University of Health Science Adana City Training and Research Hospital, Dept of Medical Pathology, Adana, TR

\* Corresponding Author: Evren Karaali E-mail: [drevrenkaraali@yahoo.com](mailto:drevrenkaraali@yahoo.com)



It also plays a significant role in the wound healing process by increasing the extra-cellular matrix synthesis through proteoglycan, collagen and protein production (6, 8, 9).

The properties demanded of wound interface material are both a broad-spectrum anti-bacterial effect and a cellular proliferative effect. Previous studies have reported that boric acid has both these properties (5, 7). The aim of this prospective, randomized, multi-center, clinical study was to macroscopically and histopathological compare the anti-microbial, angiogenetic, macrophage stimulating and epithelialization effects of boric acid sponges with silver nitrate sponges.

## Material and Methods

The study protocol was approved by the Clinical Research Ethics Committee of Health Sciences University Medical Faculty Adana Training and Research Hospital (decision no:660- MON 665.144.1, dated:08.01.2020) and by the Turkish Ministry of Health Drugs and Medical Supplies Institute (decision no: 68869993-511.06-E.27180, dated: 03.12.2019). The study was conducted in the Orthopedics and Traumatology Departments and the Plastic Reconstructive and Aesthetic Surgery Departments in 4 different university hospitals, determined by the Ministry of Health.

The study included 64 patients with chronic wounds of different etiological causes (diabetic, secondary to trauma, decubitus ulcer etc). The patients were separated as Group 1 (n:30) treated with boric acid and Group 2 (n:34) treated with silver nitrate. The wounds were evaluated macroscopically and microscopically on first presentation, then on days 7, 14, and 21, by a researcher blinded to the treatment groups. Patients were excluded from the study if they were aged <18 years or >90 years, were pregnant, had venous ulcers, septicemia/septic shock, or were receiving immunosuppressive therapy or chemotherapy.

Following patient evaluation and physical examination, randomization to the treatment groups was applied using software that included the electronic Case Report Form. In the group applied with boric acid sponge treatment, the boric acid levels were measured in blood and urine samples on days 7, 14, and 21. The general healing of the wound was evaluated with a Visual Analog Scale (VAS), also on days 7, 14, and 21.

### Technique

Boric acid sponges are produced from polyurethane, and have a broad absorption surface with pores of 400-600 $\mu$ m. On these sponges, boric acid is distributed evenly on all the surfaces at the rate of 3-5% at dimensions of 300 x 70  $\mu$ m. Silver nitrate sponges are polyurethane structures with hydrophobic properties containing silver nitrate conforming to ISO-10993-10 and ISO10993-11.

After macroscopic examination of the chronic wounds, radical debridement was performed. Deep wound cultures and biopsies were taken.

Following the application of the sponges appropriate to the postoperative wound, the same make of VAC device was applied to all the patients in both groups, using the same pressure and the same duration. The interface materials, i.e. the sponges, were changed every 7 days in all patients. No antibiotics were administered to any patient. The histopathological evaluations applied to the patients are shown in Table 1 (9).

### Statistical Analysis

Data included in the study were analyzed statistically using SPSS 21 software. Conformity of continuous variables to normal distribution was assessed with the Shapiro Wilk test. As the variables did not show normal distribution, logarithmic transformation was applied to provide normal distribution, and analysis was made with parametric methods.

The Student's t-test was applied in the comparisons of the mean values of the boric acid and silver nitrate groups in respect of the measurements taken by the clinician, the VAS scores reported by the patient, and the width, depth, and length measurements of the wound.

As the VAS scores, and the width, depth, and length measurements of the wound were taken at 4 different times, the change over time was determined using Repeated Measurements Variance Analysis, which was also used to observe time x group interaction. The re-epithelialization, granulation, inflammatory and angiogenesis measurements were evaluated categorically.

In the comparison of these measurements between the groups, the Chi-square and Fisher's Exact tests were used. In the separate comparisons of the groups of the measurements taken at 4 different times, the Marginal Homogeneity test was used.

Descriptive statistics were stated as mean  $\pm$  standard deviation, minimum and maximum values for continuous variables, and as number (n) and percentage (%) for categorical variables. A value of  $p < 0.05$  was accepted as statistically significant.

### Adverse Events:

All the adverse events were recorded on the electronic case report form, were coded according to the MedDRA coding system, and presented in detailed explanatory tables.

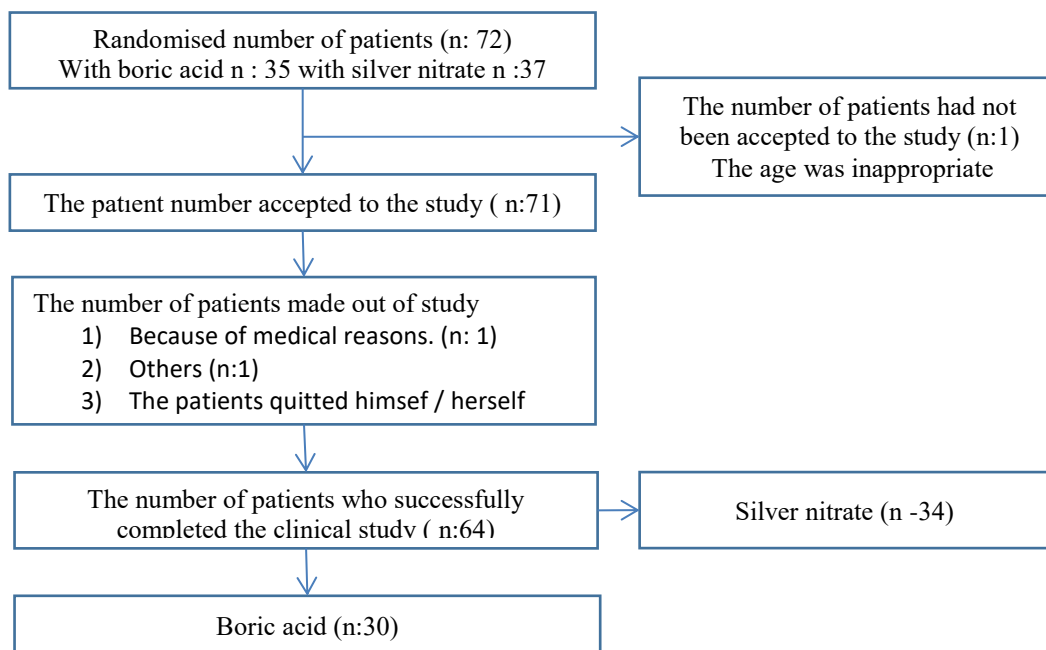
## Results

Statistical analysis of the demographic data of the patients: No statistically significant difference was determined between the groups in respect of age and height ( $p > 0.05$ ). A statistically significant difference was determined between the groups in respect of mean weight ( $p = 0.037$ ). The general demographic characteristics of the patients, such as gender, general habits, comorbidities and wound localization were seen to be homogenous in the two groups ( $p = 0.092$ ) (Table 2 and 3).

**Table 1:** The histopathological scroing of the wounds

Score	Reepitelization	Granulation	Inflammatory Cells	Angiogenesis
0	No epithelial proliferation in more than 70% of tissue	Immature and inflamed tissue in more than 70% of tissue	13-15 inflammatory cells per histopathological site	Angiogenesis deficiency, presence of bleeding, edema and congestion
1	Poor epithelization in more than 60% of tissue	Fine immature and inflamed tissue in more than 60% of tissue	10-13 inflammatory cells per histopathological area	Presence of 1-2 vessels per area, presence of bleeding, edema and congestion
2	Incomplete epithelization of more than 40% of tissues	Medium regeneration on more than 50% of texture	7-10 inflammatory cells per histopathological site	There are 3-4 vessels per area. Moderate edema congestion
3	Moderate epithelialisation in 60% of tissues.	Thick granulation tissue and well-formed collagen tissue in more than 60% of tissue	4-7 inflammatory cells per histopatological site	Presence of 5-6 vessels per area, small amount of congestion and edema
4	Completed epithelization	Finished granulation tissue	1-4 inflammatory cells per histopathological site	7 veins per field

**Table 2:** Number of patients who completed the study in accordance with the protocol



**Table 3:** Comparison of the demographic findings of both groups in terms of age, height and weight

	Boric acid		Silver Nitrate		p1
	Mean + SD	Min-Max	Mean + SD	Min-Max	
<b>Age</b>	54,43±13,2	21,00-77,0	59,68±12,4	25,00-83,00	0,108
<b>Height</b>	175,37±9,1	159,00-194,00	172,09±8,4	161,00-187,00	0,139
<b>Length</b>	80,10±15,0	55,00-110,00	87,97±14,5	62,00-113,00	<b>0,037</b>
	n	%	n	%	p2
<b>Gender</b>					
<i>Male</i>	25	83,3	22	64,7	0,092
<i>Female</i>	5	16,7	12	35,3	

**Group 1** included 30 patients, comprising 25 males and 5 females with a mean age of  $53.43 \pm 13.28$  years, mean height of  $175.37 \pm 9.10$  cm, and mean weight of  $80.10 \pm 15.03$  kg. The blood and urine values of boric acid of all the patients were at a level that could not be measured. Chronic disease in at least two systems was present in 24 patients. The wounds were localized in the foot in 18 (60%) patients, in the sacrum in 6 (20%), on the thigh in 2 (6.6%), in the gluteal region in 2 (6.6%), on the anterior wall of the chest in 1 (3.3%), and in the perineal region in 1 (3.3%). On first presentation, the wound width was mean  $57.43 \pm 62.85$  mm, length was mean  $32.73 \pm 20.66$  mm, and mean depth was  $39.37 \pm 45.95$  mm.

**Group 2** included 34 patients, comprising 22 males and 12 females with a mean age of  $59.68 \pm 12.42$  years, mean height of  $172.09 \pm 8.40$  cm, and mean weight of  $87.97 \pm 14.52$  kg. Chronic disease in at least two systems was present in 31 patients. The wounds were localized in the foot in 24 (70.5%) patients, in the sacrum in 6 (17.64%), on the thigh in 2 (5.88%), on the forearm in 1 (2.94%), and in the hand region in 1 (2.94%). On first presentation, the wound width was mean  $44.41 \pm 25.50$  mm, length was mean  $32.88 \pm 21.44$  mm, and mean depth was  $35.38 \pm 40.21$  mm.

## 2. Distribution of VAS scores at different measurement times

**2.1. Clinician evaluations:** No statistically significant difference was determined between the groups in the scoring made by the clinician at the first visit. In the boric acid group, the mean clinician score was 4.66 at baseline and decreased at subsequent measurement times to 1.50 at the final visit. The difference between the scores at the 4 measurement times was determined to be statistically significant ( $p < 0.001$ ). In the silver nitrate group, the initial clinician score was mean 4.86, and this decreased to 3.65 at the final measurement, with no statistically significant difference determined in the change over time ( $p = 0.087$ ).

**2.2. Patient Evaluation:** No statistically significant difference was determined between the groups in the scoring made by the patient at the first visit ( $p = 0.088$ ). No significant difference was determined between the groups in respect of the scoring at subsequent measurement times. In the boric acid group, the baseline mean score of 3.66 decreased statistically significantly to 1.13 at the final measurement ( $p < 0.001$ ). In the silver nitrate group, no statistically significant difference was determined between the baseline score of mean 2.89 and the final mean score of 2.21 ( $p = 0.201$ ).

**3. Blood and urine levels of boric acid:** In the blood and urine samples of the patients applied with sponges containing boric acid in the negative pressure system, boric acid was reported to be at levels that could not be measured in both analyses.

**4. Changes in culture results over time:** In Group 1, culture positivity was determined in 22/30 patients (73.3%), and of these, mixed infection was present in 12 (54.54%). The most common pathogen micro-organisms were *Staphylococcus Aureus* and *Pseudomonas Aeruginosa*. In

Group 2, culture positivity was determined in 16/34 patients, and of these, mixed infection was present in 8. The most common pathogen micro-organisms were *Staphylococcus Aureus* and *Pseudomonas Aeruginosa*. No statistically significant difference was determined between the groups in respect of the culture results ( $p = 0.705$ ). At the second visit, the number of patients with positive culture results had decreased in the boric acid group. In the comparisons made at the second, third and fourth visits, a statistically significant difference was determined between the groups in respect of culture positivity ( $p = 0.021$ ,  $p = 0.008$ ,  $p < 0.001$ , respectively).

## 5. Statistical analysis of wound dimensions:

In the boric acid group, a decrease was observed in wound width ( $p = 0.001$ ), and all the changes were found to be statistically significant compared to the previous measurements ( $p < 0.05$ ). In the silver nitrate group, no statistically significant difference was determined in the wound width over time ( $p = 0.200$ ). The difference between the groups in respect of the change in wound width over time was observed to be statistically significant ( $p = 0.010$ ).

In the boric acid group, a significant decrease in wound length was determined ( $p = 0.003$ ). The third measurement was statistically significantly different to the second measurement, and the fourth measurement to the first measurement ( $p < 0.05$ ). In the silver nitrate group, no statistically significant difference was observed in wound length over time ( $p = 0.276$ ). The difference between the groups in respect of the change in wound length over time was observed to be statistically significant ( $p = 0.019$ ).

In the boric acid group, a decrease was observed in wound depth ( $p < 0.001$ ), and all the changes were found to be statistically significant compared to the previous measurements ( $p < 0.05$ ). In the silver nitrate group, a statistically significant difference was determined in the wound depth over time ( $p = 0.002$ ) and all the changes were found to be statistically significant compared to the previous measurements ( $p < 0.05$ ). The difference between the groups in respect of the change in wound depth over time was observed to be statistically significant ( $p = 0.002$ ) (Table 4).

**6. Analysis of adverse events:** In 3 (4.22%) patients, an adverse event was reported, one of which was recorded as "possibly" related to the drug used, and 2 as "probably". All the adverse events that developed were identified as silver allergy.

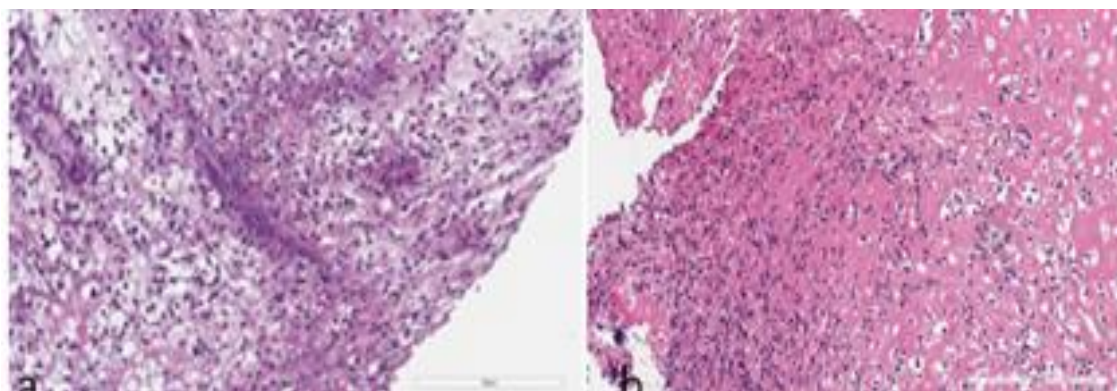
## 7. Macroscopic and microscopic features of the wounds and the statistical analysis of the changes over time

On day 7, there were small foci of necrosis and the wound surfaces were inflamed in both groups. A shrinking of the wound size was not determined at this stage, and similar microscopic features were present in both groups. Generally, in addition to lymphocyte and macrophage predominance, there was observed to be endothelial damage and capillary vasoconstriction. On day 14, there was a noticeable vascular proliferation in both groups, and this was more evident in Group 1 (Figure 1 and 2).

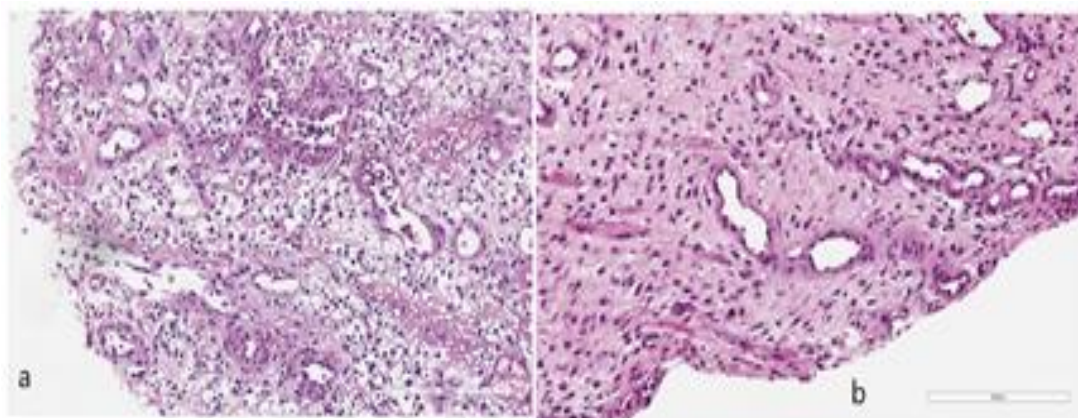


**Table 4:** Comparison of the wounds before and after treatment in 3D

		Boric acid		Silver Nitrate		p <sub>group</sub>	p <sub>general</sub>
Wound size		Mean+SD	Min-Max	Mean +SD	Min-MaX		
Width	Pre-treatment	57,43±62,8	10-350	44,41±25,5	15-110	0,570	0,006
	Pot-treatment	38,83±43,32	0-230	43,18±26,1	0-110	0,132	
	Ptime	<0,001		0,276			
Length	Pre-treatment	32,73±20,6	8-75	32,88±21,4	5-75	0,885	0,021
	Post-treatment	26,00±23,2	0-100	40,68±33,7	0-170	0,068	
	Ptime	0,008		0,756			
Depth	Pre-treatment	39,37±45,9	5-200	35,38±40,2	6-170	0,862	0,006
	Post-treatment	18,33±24,1	0-90	25,44±31,4	0-115	0,096	
	P time	<0,001		0,008			



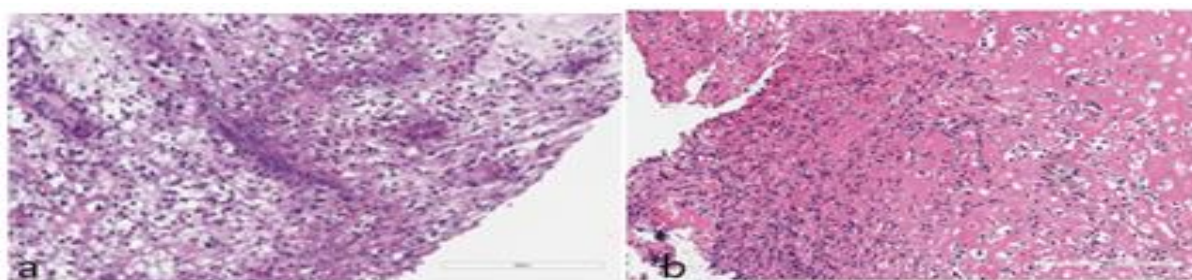
**Figure 1:** Histopathological images of first application biopsies. a: The patient who is applied a silver sponge. Ulceration of the squamous epithelium and fibrinoleukocytic exudate. b: The patient was treated with Acid Boric. Biopsy: Surface ulceration of squamous epithelium, fibrinoleukocytic exudate, Hematoxylin Eosin staining x200



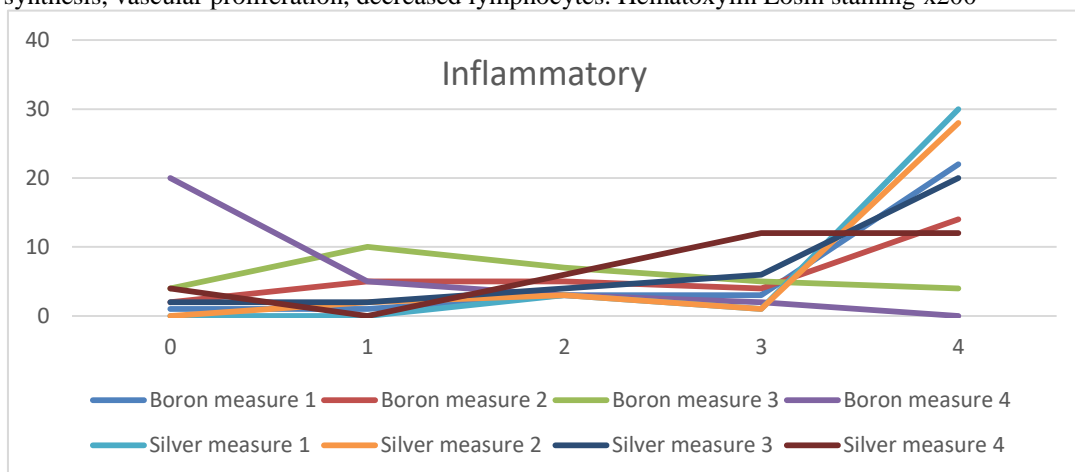
**Figure 2:** Histopathological images of specimens taken on the 7th day. (a): The patient who was treated with a silver sponge. Vascular proliferation by dense neutrophilic polymorphs and lymphocytes. (b) The patient to whom a boron sponge is applied. Vascular proliferation, collagen synthesis, lymphoplasmacytic cell infiltration. Hematoxylin Eosin staining x200

On day 21, macroscopically vascularization of the wound bed was seen to be better in Group 1, and the wound diameter had shrunk noticeably from the periphery. These features were less evident in Group 2. Microscopically, vascular proliferation, fibroblastic activation, and epithelialization were more intense in Group 1. These features were present in Group 2, but not so intensely (Figure 3).

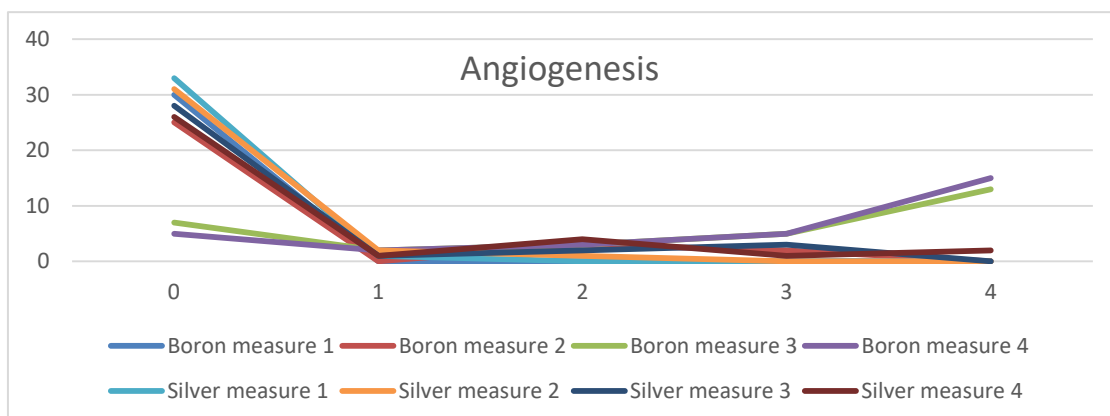
**7.1a. Inflammation phase and cell characterization:** In the boric acid group and the silver nitrate group, the ratio of inflammatory cells showed a statistically significant change at all measurement points compared to the previous measurement ( $p < 0.05$ ,  $p < 0.05$ ). A statistically significant difference was determined between the boric acid group and the silver nitrate group in respect of the ratio of inflammatory cells at the final measurement ( $p < 0.001$ ) (Graphic 1).



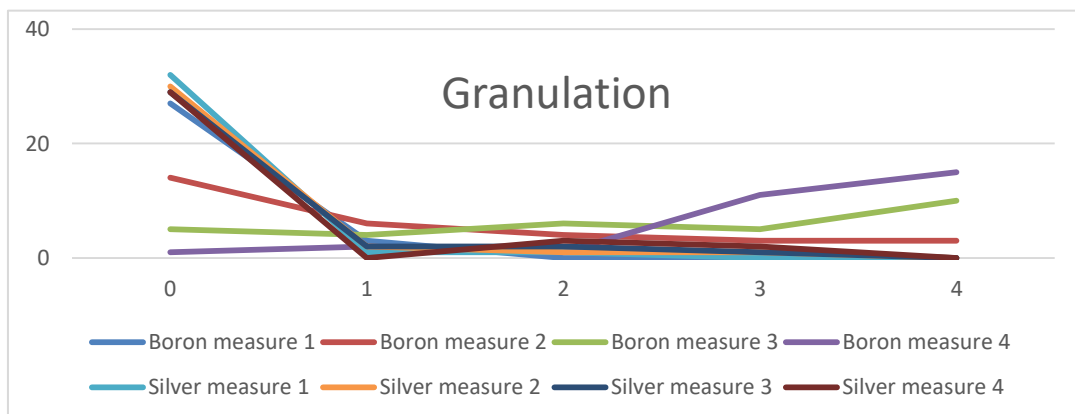
**Figure 3:** Histopathological images of specimens taken on the 14th day. (a) Patient with silver sponge applied Vascular proliferation and lymphoplasmacytic cell infiltration. (b) The patient to whom a boron sponge is applied. Pronounced collagen synthesis, vascular proliferation, decreased lymphocytes. Hematoxylin Eosin staining x200



**Graphic 1:** Comparison of inflammation level among two different groups at different visits



**Graphic 2:** Comparison of angiogenesis between two different groups at different visits



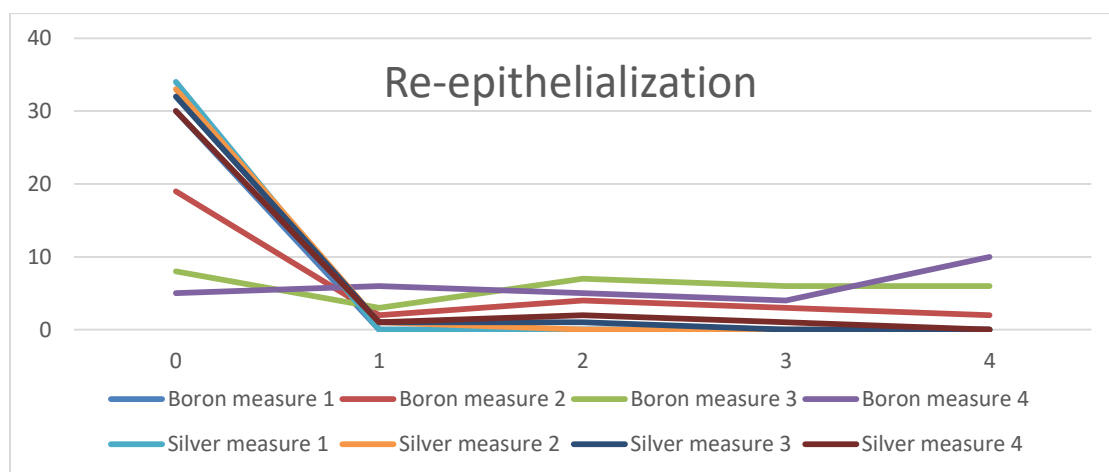
**Graphic 3:** Comparison of granulation between two different groups at different visits

**7.1b. Angiogenesis:** In the boric acid group the rate of angiogenesis showed a statistically significant change at all measurement points compared to the previous measurement ( $p < 0.05$ ). In the silver nitrate group, no statistically significant change was seen at all measurement points compared to the previous measurement ( $p > 0.05$ ). A statistically significant difference was determined between the boric acid group and the silver nitrate group in respect of the angiogenesis rate at the final measurement ( $p < 0.001$ ) (Graphic 2).

**7.1c. Granulation:** In the boric acid group the rate of granulation showed a statistically significant change at all measurement points compared to the previous measurement ( $p < 0.05$ ). In the silver nitrate group, a statistically significant change was seen in the granulation rate of the second measurement compared to the first measurement ( $p < 0.05$ ). No significant change was seen between the third and second measurements or between the fourth and third measurements in the silver nitrate group ( $p > 0.05$ ).

No statistically significant difference was determined between the boric acid group and the silver nitrate group in respect of the first and second measurements of the granulation rate ( $p < 0.05$ ), and the difference between the groups at the final measurement was statistically significant ( $p < 0.001$ ) (Graphic 3).

**7.1d. Re-epithelialization:** In the boric acid group the rate of re-epithelialization showed a statistically significant change at all measurement points compared to the previous measurement ( $p < 0.05$ ). In the silver nitrate group, no statistically significant change was seen at all measurement points compared to the previous measurement ( $p > 0.05$ ). A statistically significant difference was determined between the boric acid group and the silver nitrate group in respect of the re-epithelialization rate at the final measurement ( $p < 0.001$ ) (Graphic 4).



**Graphic 4:** Comparison of re-epithelialization between two different groups at different visits

## Discussion

It is estimated that by 2040 there will be 640 million patients diagnosed with diabetes, and it is thought that 10% of these will have diabetic ulcers (10). Despite these data, chronic wounds continue to be one of the largest and growing problems around the world. In particular, the rapid increase in the geriatric population has caused an increase in the prevalence of diabetes mellitus and other chronic diseases, and an increase in the incidence of chronic wounds. In addition to having a negative effect on quality of life, chronic wounds are comparable to cancer in respect of mortality rates (11-13).

The optimal physiochemical properties of sponges applied as the intermediate unit in NPWT systems, are still not fully known (14, 15). Silver nitrate is currently used as the filling material in sponges. Silver is an effective bactericide against both gram-positive and gram-negative bacteria. However, at high concentrations, it is toxic to mammalian cells. Complications of silver such as leukopenia, kidney and liver dysfunction, and neuropathy are still unresolved severe problems (16-20).

Another agent which is accepted as broad-spectrum is boric acid, which has been shown in several studies to be effective against bacteria such as *S. aureus*, *K. pneumoniae*, *C. Albicans*, *A. Niger*, *E. coli*, and *P. Aeruginosa* (21, 22). In a recent study was compared boric acid sponges and silver nitrate sponges, and they reported that anti-infective properties were much more evident in boric acid sponges compared to silver nitrate sponges (23). In addition to the anti-infective property of boric acid, the authors claimed that this effect was formed by the proliferation of local and systemic defense cells. In the current study, culture positivity was determined in 73.3% of the patients in the boric acid group, and 54.54% of those patients had mixed-type infection. No statistically significant difference was determined between the two groups in respect of culture positivity on first presentation, whereas a significant difference was observed in the final culture results ( $p < 0.001$ ).



Various studies have shown that boric acid shows notable antimicrobial effects against yeast and fungi and significantly increases cellular proliferation, macrophage migration, growth factor and dermal cell gene expression (24-26). In another study, it was reported that boric acid played an important role in the wound healing process by increasing extra-cellular matrix synthesis through proteoglycan, collagen and protein production (6). In the current study, the wound healing process was evaluated microscopically and macroscopically. Macroscopic evaluation of the wound was made according to metric measurements of the wound dimensions and VAS scores. In the metric evaluation of the wound dimensions in particular, there was a significant decrease in wound width in the boric acid group ( $p=0.001$ ), and there was no statistically significant difference in the wound width compared to the baseline measurement or over time in the silver nitrate group ( $p=0.200$ ). While a significant decrease was seen in wound length in the boric acid group ( $p=0.003$ ), no significant difference was determined over time in the silver nitrate group ( $p=0.276$ ). The wound depth showed a significant difference over time in the boric acid group ( $p<0.001$ ) and no difference was determined in the silver nitrate group ( $p>0.05$ ).

In the scoring applied by the clinicians, no significant difference was determined between the groups at the first visit, and in the subsequent visits, significant differences were determined between the groups at each measurement time ( $p<0.001$ ). In the silver nitrate group, no statistically significant difference was found in the subsequent clinician evaluations compared to the baseline measurement ( $p=0.087$ ). In the subjective patient evaluation (VAS), no significant difference was determined between the groups in the initial evaluation ( $p=0.088$ ). In the comparisons of the groups at subsequent visits, significant differences were observed in favor of the boric acid group ( $p<0.001$ ).

When the cases were examined microscopically, although there was no significant difference in the histopathological features of the biopsies taken at 7 days compared to the first presentation, there was observed to be a decrease in chronic inflammatory cells such as lymphocytes and macrophages in both groups. However, there was no statistically significant difference between the two groups in respect of the number of inflammatory cells. In the boric acid group, chronic inflammatory cells were seen to be extremely sparse at this stage and the most important formation was a noticeable vascular germination.

At this stage, there was no significant difference between the groups in respect of inflammatory cells, angiogenesis, granulation, or epithelialization. As a result of the histopathological examination of the final biopsies taken on day 21, significant differences were determined at every stage in the boric acid group. Although vascular proliferation, fibroblastic activation, and granulation tissue were clearly noticeable at this stage, they were less evident in the silver nitrate group.

As a result of the macroscopic evaluation, the boric acid sponges were determined to have shrunk the wounds in all three dimensions. Furthermore, in the microscopic

analyses, cell proliferation was determined to be responsible for wound healing. The determination of statistically significant improvements, especially in vascular proliferation, fibroblastic activation and granulation tissue, seemed to confirm the theory that boric acid had proliferative effects on a cellular basis.

Although this was a multi-center, prospective, randomized study, there were also limitations of the low number of cases included and that the results were not examined at the molecular level.

## Conclusion

The results of this study showed that while the inflammatory cell count and ratios were similar in both groups on first presentation, there was a significant decrease in inflammatory cells in the boric acid group as the treatment progressed over time. In the silver nitrate group, there was no noticeable decrease in inflammatory cells even at the late stages. In the samples taken at the second and third measurement points, the formation of collagen was seen to have started earlier and in broader areas in the boric acid group. Collagen formation started later in the silver nitrate group and was observed in a few focal areas. Vascular proliferation was seen at an early stage in the boric acid group and angiogenesis increased more as the treatment progressed. However, in the silver nitrate group, vascular proliferation was less evident and was observed to be focal. In the samples taken at the final examination, epithelialization had started in both groups, and was more evident in the boric acid group.

In addition to anti-microbial effects, boric acid sponges can be considered to form a synergic effect with the NWPT system in cell proliferation, differentiation and migration, which are necessary for wound healing. The use of these sponges can be considered a good alternative to silver nitrate sponges, which also have a broad-spectrum anti-microbial effect, but for which the same effect could not be determined in cell proliferation.

**Author Contributions:** AK, EK, TS, EF, İA, AAÖ, OB, BS, AU, ÖK, MB: Project design, Review of the literature, Data collection AK: Writing and Revisions

**Conflict of interest:** No actual or potential conflicts of interest exist in relation to this article.

**Ethical issues:** All authors declare originality of research.

## References

1. Falanga V. Classifications for wound bed preparation and stimulation of chronic wounds. Wound repair and regeneration: official publication of the Wound Healing Society [and] the European Tissue Repair Society. 2000;8(5):347.
2. Gaisford S, Beezer A, Bishop A, Walker M, Parsons D. An in vitro method for the quantitative determination of the antimicrobial efficacy of silver-containing wound dressings. International journal of pharmaceutics. 2009;366(1-2):111.
3. McDonnell G, Russell AD. Antiseptics and Disinfectants: Activity, Action, and Resistance. Clinical Microbiology Reviews. 1999;12(1):147.



4. Siegel HJ, Herrera DF, Gay J. Silver Negative Pressure Dressing With Vacuum-assisted Closure of Massive Pelvic and Extremity Wounds. *Clinical Orthopaedics and Related Research*. 2014;472(3):830.
5. Borrelly J, Blech M, Grosdidier G, Martin-Thomas C, Hartemann P, editors. Contribution of a 3% solution of boric acid in the treatment of deep wounds with loss of substance. *Annales de chirurgie plastique et esthetique*; 1991.
6. Nzietchueng R, Dousset B, Franck P, Benderdour M, Nabet P, Hess K. Mechanisms implicated in the effects of boron on wound healing. *Journal of trace elements in medicine and biology: organ of the Society for Minerals and Trace Elements (GMS)*. 2002;16(4):239.
7. Tepedelen B, Soya E, Korkmaz M. Boric Acid Reduces the Formation of DNA Double Strand Breaks and Accelerates Wound Healing Process. *Biological trace element research*. 2016;174(2):309.
8. Samman S, Foster M, Hunter D. The Role of Boron in Human Nutrition and Metabolism. *Boron Science: New Technologies and Applications*. 2016:73.
9. Gupta A, Kumar P. Assessment of the histological state of the healing wound. 2015.
10. Armstrong D, Wrobel J, Robbins J. Guest Editorial: are diabetes-related wounds and amputations worse than cancer? *International wound journal*. 2007;4(4):286.
11. Hopman W, Harrison M, Coe H, Friedberg E, Buchanan M, VanDenKerkhof E. Associations between chronic disease, age and physical and mental health status. *Chronic diseases in Canada*. 2009;29(3):108.
12. Bickers DR, Lim HW, Margolis D, Weinstock MA, Goodman C, Faulkner E, et al. The burden of skin diseases: 2004: A joint project of the American Academy of Dermatology Association and the Society for Investigative Dermatology. *Journal of the American Academy of Dermatology*. 2006;55(3):490-500.
13. Kapukaya R, Ciloglu O. Treatment of tibial intercalary defects secondary to tumour with modified fibular flap technique. *European Journal of Plastic Surgery*. 1-8.
14. Orgill D, Manders E, Sumpio B, Lee R, Attinger C, Gurtner G, et al. The mechanisms of action of vacuum assisted closure: more to learn. *Surgery*. 2009;146(1):40.
15. Wu M, Sun M, Dai H, Xu J, Guo R, Wang Y, et al. Negative-pressure wound therapy: An effective adjunctive treatment to assist flap survival and wound closure. *Journal of plastic, reconstructive & aesthetic surgery: JPRAS*. 2018;71(11):1664.
16. Sudmann E, Vik H, Rait M, Todnem K, Andersen K, Julsham K, et al. Systemic and local silver accumulation after total hip replacement using silver-impregnated bone cement. *Medical progress through technology*. 1994;20(3-4):179.
17. Trop M, Novak M, Rodl S, Hellbom B, Kroell W, Goessler W. Silver-coated dressing acticoat caused raised liver enzymes and argyria-like symptoms in burn patient. *The Journal of trauma*. 2006;60(3):648.
18. Chung I, Lee M, Shin D, Jung H. Three systemic argyria cases after ingestion of colloidal silver solution. *International journal of dermatology*. 2010;49(10):1175-7.
19. Wan A, Conyers R, Coombs C, Masterton J. Determination of silver in blood, urine, and tissues of volunteers and burn patients. *Clinical chemistry*. 1991;37(10 Pt 1):1683.
20. Drake P, Hazelwood K. Exposure-related health effects of silver and silver compounds: a review. *The Annals of occupational hygiene*. 2005;49(7):575.
21. Özcan KM, Sitesi Y, Blok A. The efficacy of boric acid in otomycosis: an in vitro study. *Mediterr J Otol*. 2005;2:00-.
22. Yılmaz MT. Minimum inhibitory and minimum bactericidal concentrations of boron compounds against several bacterial strains. *Turkish Journal of Medical Sciences*. 2012;42(Sup. 2):1423-9.
23. Kapukaya R, Ciloglu O. Treatment of chronic wounds with polyurethane sponges impregnated with boric acid particles: A randomised controlled trial. *International Wound Journal*. 2020;17(5):1159-65.
24. Doğan A, Demirci S, Çağlayan A, Kılıç E, Günel M, Uslu U, et al. Sodium pentaborate pentahydrate and pluronic containing hydrogel increases cutaneous wound healing in vitro and in vivo. *Biological trace element research*. 2014;162(1-3):72.
25. Demirci S, Doğan A, Karakuş E, Halıcı Z, Topçu A, Demirci E, et al. Boron and Poloxamer (F68 and F127) Containing Hydrogel Formulation for Burn Wound Healing. *Biological trace element research*. 2015;168(1):169.
26. Demirci S, Doğan A, Aydın S, Dülger E, Şahin F. Boron promotes streptozotocin-induced diabetic wound healing: roles in cell proliferation and migration, growth factor expression, and inflammation. *Molecular and cellular biochemistry*. 2016;417(1-2):119.