

Idiopathic scoliosis. Mechanisms of development

MD. Prof. Dr. Late Serdyuk Valentyn Viktorovich¹, Serdiuk Oleksandr Valentinovich¹, Tishkin Grigory Vladimirovich^{1*}

¹ Odessa National Medical University, Dept. of Orthopaedics, Odessa, Ukraine
<https://orto-serdyuk.com/>

* **Corresponding Author:** Tishkin Grigory Vladimirovich **E-mail:** grishatishkin@gmail.com

ABSTRACT

Objective: One of the most complicated problems of Orthopaedics is the treatment of scoliosis. More than 90% of cases are attributable to Idiopathic deformation, the cause of which is unknown. We investigated the cause of pathogenesis of this disorder.

Methods: At our institution more than 6900 patients aged 1-89 years have undergone inpatient and outpatient treatment in connection with spinal pain syndrome and different neurological disorders associated with idiopathic scoliosis. This study was undertaken between February 1996 and February 2010. All patients had a clinical, radiography and laboratory examinations.

Results: The 29.6% of patients were aged 31-50 years old. 60% were men and 40% were women. While examining patients with scoliosis deformation, we noted symptoms of body asymmetry i.e. different volumes of the right and left halves of face body and limbs. These features were typical for all patients irrespective of sex, age, and ethnic origin. 83,2% of patients had underdevelopment of the left part of the body, and only 16,8% of the right side. Analysis of published work in anatomy, physiology, neurophysiology, vertebrology, done simultaneously with analysis of the clinical material, allowed us to make some conclusions.

Conclusions: First asymmetrical structure of the human body is based on laws of nature and is linked with difference of sizes of brain's hemispheres, particularly of the right and left gyrus centralis anterior which controls the muscle's function and our movements. Second asymmetrical tension of Erector spinae muscles, leads to inclination of the pelvis on a side of weak muscles; thus initiating development of the lateral spine curves. Since such a situation is typical for all people, this deformation is known as functional scoliosis. Third, further development of the bodies of vertebrae, their arches, processes, intervertebral discs, ligaments, and other anatomical elements in position of the deviation leads to one sided underdevelopment of these structures. As a result the areas of instability appear in each segment of spine (neck, chest, lumbar and sacral areas).Fourth, the muscles in a growing body misbalance and on the ground of rotating movement, start rotatory dislocation of vertebrae in zones of instability in all parts of the spine. As a result torsion of the deformed wedge-shaped vertebrae leads to formation of the structural scoliosis. The rotation of the vertebrae, described above, does not depend on sex, age and ethnic origin of the patient and has a character of the natural development. Thus from our point of view, the term idiopathic scoliosis, must be changed to spinal muscle asymmetrical deformation of a reflex origin. Understanding of this rotation allowed us to establish an effective non-surgical method of treatment of scoliosis and spinal pain syndrome in patients of all ages.

Key words: scoliosis, idiopathic

Research Article

Received 09-11-2021

Accepted 18-11-2021

Available Online: 22-11-2021

Published 30-11-2021

Distributed under
Creative Commons CC-BY-NC 4.0

OPEN ACCESS



INTRODUCTION

Treatment of scoliosis remains a great challenge of orthopedics and has a long history. Physicians of antiquity were concerned with this problem – Pythagoras, Hippocrates and Claudius Galen; the latter have proposed the terms scoliosis, kyphosis and lordosis. Since then, centuries have passed, but the significance of the issue has remained unchanged. Earlier studies of foreign and local investigators were aimed at discovering the ethology of scoliosis. These studies have established that idiopathic scoliosis (IS) or lateral curvature of the spine of unknown ethology is the most frequent among various spinal deformities

(rachitic, cicatricial, paralytic, reflex-painful, discogenic, endocrine, hysterical, emphysematous, hereditary, post-traumatic and others) and constitutes more than 90% of lateral deformities of the spine.

Based on our own significant clinical material, we have set ourselves the goal to reveal the etiopathogenesis of this disease.

MATERIAL and METHODS

From February 1996 till February 2010, we have observed and managed more than 6900 patients aged 1-89 years. These patients suffered from spinal pain, various somatic and neurologic impairments associated with idiopathic deformities of the spine and were managed in the outpatient setting. The majority of patients were 31-50 years of age; 60% were female, 40% - male.

While examining patients with scoliotic deformity, we have always observed signs of asymmetry of the body – different sizes and volumes of the halves of the face, trunk and extremities. These signs were typical for all the patients independent of sex, age and race. Among our patients, we observed underdevelopment of the left side of the body in 83.12% of cases and only in 16.88% - of the right side.

All patients underwent clinical, radiological and laboratory assessments and other tests, if required.

RESULTS and DISCUSSION

Despite numerous scientific papers and publications on the etiology of idiopathic scoliosis the findings were not of a general nature. Since all the studies, including our own, either directly or indirectly were based on the study of the nature of the asymmetry of the body, we decided to arrange the questions in a certain order:

1. What causes the development of the asymmetry of the body?
2. How the lateral curvature of the spine is forming?
3. What comes first – lateral curvature or muscle asymmetry?
4. What are their interrelations?

In search of answers to these questions, we have studied works of classics of domestic and foreign orthopedics, as well as works of experts in anatomy and physiology [1, 2, 4, 5, 14].

We start the presentation of the results of this analysis with neurophysiological issues.

Anatomy and physiology of interhemispheric differences

Since 1968 papers on the results of post mortem examination of multiple preparations of the human brain were published [1, 2, 13, 14] and significant anatomical differences between hemispheres were reported. The area of the temporal cortex, which overlaps Wernicke's area (responsible for semantic speech and also known as Planum Temporale), was notably greater in the left hemisphere in approximately 70% of cases (Fig. 1 and 2).

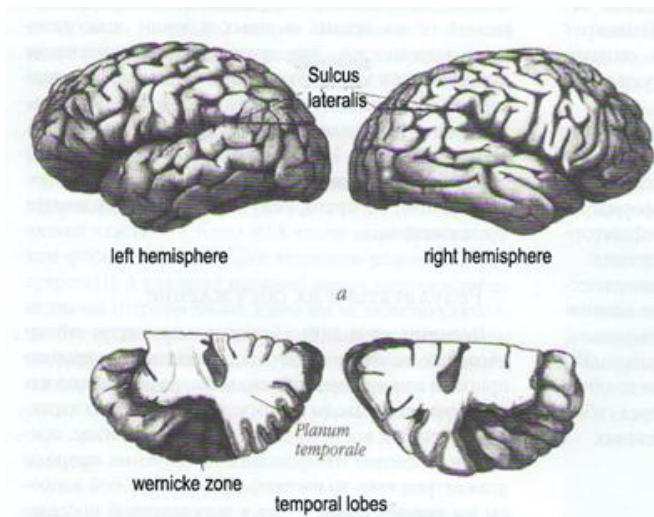


Figure 1. Anatomical asymmetry of cerebral hemispheres. A – Sylvian fissure in the right hemisphere curves upwards at more acute angle; B – posterior part of the Planum Temporale is usually much larger in the left hemisphere, which is associated with verbal functions.

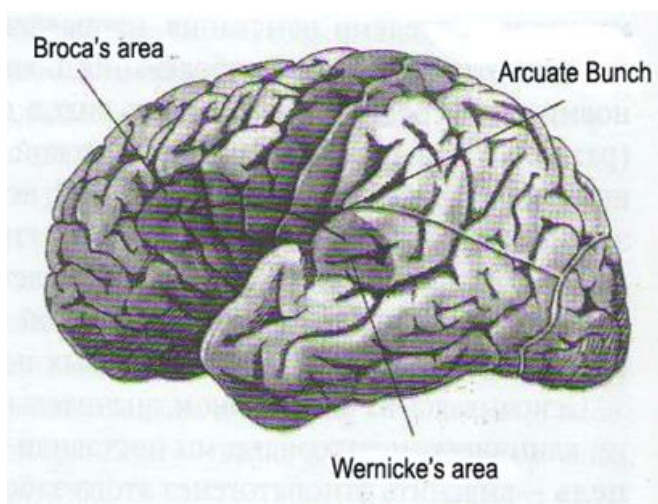


Figure 2. Areas of the left hemisphere involved in speech and its perception. Wernicke's and Broca's areas are interconnected via fibrous tract – so-called fasciculus arcuatum (indicated with the arrow, because this structure is not externally visible).

This asymmetry was also typical for the brain of human fetus. It was demonstrated that Sylvian fissure – a deep sulcus in the cerebral cortex, which separates temporal lobe from the rest of the cortex in the left hemisphere is longer and straighter and is more curved upwards in the right hemisphere. Such asymmetry was also identified in fossil skulls of humans (Neanderthals), which allowed the investigators to suggest that asymmetry of the hemispheres is likely a part of human genetic heritage.

Long-term psychological studies have demonstrated other very important details on brain physiology. Thus, it was shown that in most cases, women are superior to men in verbal skills. These differences are already seen in childhood. Girls begin to talk and read earlier than boys [1, 13, 14].

We introduce to the reader another area that deals with the structure and functioning of cerebral hemispheres in the

prenatal (intrauterine) period. Thus, from the 6th week after fertilization, gonads (sex glands) are formed that initially are the same in both sexes. In male fetus on the 3rd month of intrauterine development gonads start to differentiate to form the testes and secrete male hormone – testosterone under the influence of one or more genes of Y-chromosome. Although testosterone is present in low concentrations in female fetus (certain amount of this hormone is produced in the maternal organism) the level of this hormone in male fetus greatly increases after formation of testes; this inhibits the growth of the left hemisphere and contributes to the development of relatively greater right hemisphere in males [1, 13, 14].

- Thereby, we have established the following: left and right cerebral hemispheres are asymmetric, which is predetermined genetically.

Broca's area – a specific zone of the frontal lobe of the left hemisphere that controls all muscles of the face, tongue, jaws and throat. This is achieved through connections of this area with the anterior central gyrus – area of the cerebral cortex that is responsible for motor functions of the right side of the body. Thus, Broca's area can be called motor center for speech.

Wernicke's area – posterior part of the first temporal gyrus, which is responsible for the semantic speech. In 65-70% of cases this area of cerebral cortex is larger in the left hemisphere.

Wernicke's and Broca's areas are interconnected through the arcuate fasciculus that provides synchronous function, i.e. motor and semantic speech constitute a single process.

Given the functional connection of Broca's and Wernicke's areas one can assume that these areas are functioning more active in the left hemisphere than in the right. This causes the muscle tone of the right side of the body to increase in head and neck muscles, as well as in the spine extensors (Fig. 3). As a result of their asymmetrical contractility, relative shortening of the lower limb of the weaker side occurs and the trunk tilts to the left. Interestingly, that this hypertonus is also typical for mimic muscles, which may serve as an explanation of facial asymmetry.

In those individuals (11%), in whom Planum Temporale is more developed in the right hemisphere, hypertonus of the spine extensors on the left side causes subsequent tilt of the body to the right. It is what we call a "relative shortening of the right leg" (Fig. 4).

High testosterone level during the prenatal period inhibits the growth of the left hemisphere in male fetus compared to females. In boys, such underdevelopment of the left hemisphere and particularly Wernicke's area explains why boys 4 times more frequent than girls are among children who are unable to read, and why girls have more developed verbal skills compared to boys.

If we assume that Broca's and Wernicke's areas in girls are 4 times more active compared to boys, than the latter also have 4-fold increased muscle tone of the spine extensors on the right side. Moreover, considering the fact that the left hemisphere is smaller in boys compared to girls, the difference in muscle tone of the trunk muscles increases even more. Probably, this may explain the universally known fact

that lateral (scoliotic) curvature in girls occurs 5-6 times more often than in boys.

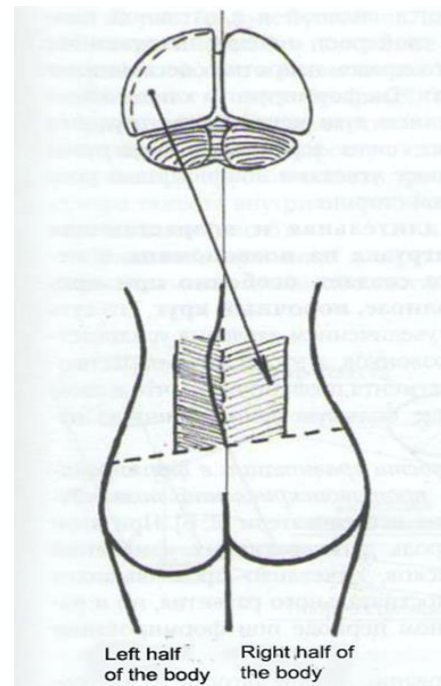


Figure 3. Hyper tonus of spinal extensors on the right is due to increased functional activity of anterior central gyrus of the left hemisphere.

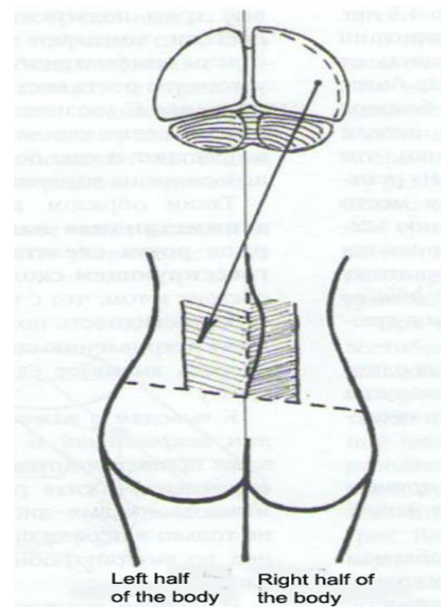


Figure 4. Hypertonus of spinal extensors on the left is due to increased functional activity of anterior central gyrus of the right hemisphere.

As a newborn child gets older, asymmetry of the trunk muscles "fixes" in the cerebellum, which controls all types of movements. Indeed, the cerebellum is often called "the keeper of conditioned reflexes". Months will pass from standing, first and subsequent steps to a stable upright posture and steady walking.

From our point of view precisely during this period conditioned reflex of the vertical body position is formed.

In girls, this process occurs faster than in boys, thus they begin to walk earlier. However, this conditioned reflex (let us call it "vicious"), unfortunately fixes wrong position of the body tilted to the right or to the left. This child comes to life and remains the same in subsequent periods of his/her life, unless he/she will meet a competent orthopaedist!

Thus, why do anatomists consider body curvature to be normal? Indeed, it is typical for every human.

Thus, giving answers to the questions raised earlier, we may conclude that the asymmetry of the body occurs due to specifics of brain functioning and its development; asymmetry begins to form already at the fetal stage. Newborn baby already has asymmetry of the trunk muscles. Later, when he/she begins to walk due to different degree of tension of the spinal extensors on the left and the right sides leads to the development of the lateral spinal curvature, which should be called physiological scoliotic posture or functional scoliosis.

As for the degree of body distortion and the transition from physiological to pathological state (scoliotic disease), it depends both on the tone of the trunk extensors and on the structural features of the spine, which are genetically determined. Increasing shortening of one of the lower extremities plays significant role in the progression of deformation. In this case, we don't consider a variety of specific and nonspecific pathological processes that may affect the structure of the musculoskeletal system.

The above said allows to conclude that since the intrauterine period of human development up to birth only cerebral mechanism acts to provide the development of lateral curvature of the spine. However, after birth other than cerebral factors are involved. Various theories of the etiology of scoliosis are based on the analysis of these factors, which we have discussed earlier.

It should be mentioned that many scientists have tried to investigate the nature of the asymmetry of the body. One of these was of considerable theoretical and practical interest and answered on one of the questions stated above: what comes first – lateral curvature or muscle asymmetry [15]. The author experimented on young monkeys, aged from 1 to 1.5 years. Surgery consisted of unilateral extirpation of the common trunk extensor (m. erector trunci) from the sacrum to the lower part of the chest. In a month lateral curvature of the spine has developed. During subsequent 3-4 weeks wedge-shaped vertebrae appeared as a result of asymmetric growth. Radiographic picture was the same as in humans with scoliosis. Thus, according to the investigator, the primary cause of the development of scoliotic deformity in experimental animals was unilateral spasm of the preserved common spinal extensor, which caused pelvic tilt toward weak muscles.

Other investigators also pointed at the significance of contractures of spinal muscles as one of the first signs of scoliosis progression in infancy [12].

Importantly, we have come to this conclusion by ourselves, while examining the spines of breastfed children.

On 11th International Symposium on Scoliosis (London, 2006) several reports on the same issue were presented. Particularly, an association was found between adolescent IS and asymmetric anatomy and function of the cerebral and cerebellar hemispheres [7, 10].

An experimental porcine model of unilateral paralysis of spinal extensors was created using toxin of *Clostridium botulinum*. This caused lateral curvature of the spine in thoracic region on the side of paralyzed muscles. Another investigators have suggested that the primary cause of IS and associated spinal pain is impaired balance of muscles supporting the spine, which is in turn caused with the different activity of cerebral hemispheres [8, 9].

Contemporaneously, other possible causes of spinal deformities were studied, particularly, the effect of gravity on the body position in space and development of curvatures and anti curvatures of the spine [3, 4]. The authors have presented their point of view on the causes of IS:

1. Progressive unilateral contracture of paravertebral muscles observed in scoliosis already in infancy provides a basis for structural changes of the spine.
2. Development of structural scoliosis is the result of asymmetric growth of vertebrae.
3. With the beginning of walking even a slight curvature of the spine immediately impairs its dynamic equilibrium. On the concave side of the curvature pressure is higher compared to the convex side.

We remind the reader that according to law of Hueter-Volkman, areas of bone where epiphyseal cartilage is exposed to severe and prolonged compression grow slower and less loaded areas of epiphyseal cartilage, therefore, provide acceleration of bone growth. Thus wedge-shaped vertebrae are formed. With increasing curvature arc of the thoracic spine, the forces of vertical load are also increasing, thus suppressing epiphyseal growth of vertebrae on the concave side.

In this way, prolonged and increasing asymmetric load on the spine during the period of active growth of the skeleton, especially in cases of progressive scoliosis, creates so-called "vicious circle". Its essence is in the fact that increasing pressure potentiated wedge-shape deformity of vertebrae and this leads to increasing deformation of the spinal segment, which in turn causes even greater asymmetrical load.

Other researchers have come to conclusions regarding the significance of gravity in the formation of curvatures and anti curvatures of the spine [2, 6]. At the same time the important role of degenerative changes of intervertebral discs was emphasized, which is clearly seen during postnatal development and even earlier – during intrauterine period. Finally, Australian investigators [11] came to the conclusion that gravity-associated tilting of the body (of the spine) is a potential cause of rotational displacement of vertebrae in IS.

Summarizing the given material on the etiology of IS it may be concluded that a man is born with rotated vertebrae as a result of asymmetry of spinal extensors. But when he/she begins to walk, further progression of rotation of separate vertebrae and their groups is potentiated with the forces of gravity; this is the main cause of initially physiological

curvature and then pathological deformation of the spine. This is the nature of the spinal mechanism of development of the lateral curvature of the spine.

So, we have given answers on all the questions stated above. There is only one uncertainty remained – what made vertebrae to rotate relative to each other in all regions of the spine (cervical, thoracic, lumbar and sacral)? Why lateral flexion of the spine inevitably lead to their rotation and torsion? To answer this questions we have studied the biomechanical aspects of vertebral torsion. The essence of the study is presented below (the section was written in collaboration with Associate Professor of Theoretical Mechanics and Mechanical Engineering of Odessa National Polytechnic University, PhD in Technical Sciences, Svinarev YN).

Rotatory displacement of vertebrae relative to each other in spine bending – justification from biomechanical perspective

According to the laws of mechanics, an object will remain stable only if the projection of its center of gravity lies within the area delineated by the bearings of the object (Fig. 5). The object shown in Fig. 5a will be stable, and the object in Fig. 5b – will tip over. This statement remains applicable to biomechanics of the human body.

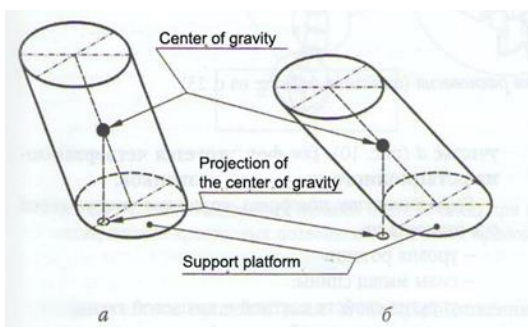


Figure 5: Center of gravity, projection of center of gravity, supporting site. **A-** stable object, **B-** unstable object.

Cerebellum and vestibular apparatus of the inner ear, which control the vertical position of the body and its movements in space, projects center of gravity within the supporting area bounded by feet in order to provide maximum stability of the body (Fig. 6).

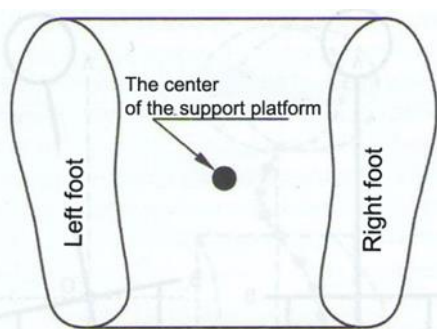


Figure 6: Supporting site. Center of supporting site, left feet, right feet

In bending of the trunk and pelvic tilt caused with an absolute and (or) relative shortening of the leg axis of the spine (Fig. 7a) deviates from the vertical axis, shifting the center of gravity towards the tilt (Fig. 7b).

At the same time, spinal muscles bend the spine in a direction opposite to the deviation of the center of gravity in order to preserve balance (Fig. 7c).

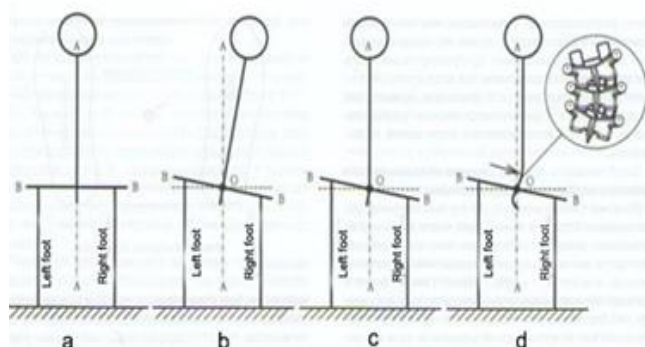


Figure 7. Curvature of the spine without impairment of balance.

If the tilt could be counterbalanced with rotation of only one vertebra in a vertical plane then the spine would acquire vertical position bending at the point O, as shown on Fig. 7c; the center of gravity would return to the axis of symmetry A-A and stability of the body would be restored and the spine above the point O would preserve its straightness.

In fact, possible relative motions of vertebrae allow the spine to bend to a desired angle only through simultaneous rotation of a few adjacent vertebrae (Fig. 8a). As a result, the spine bended in the region c over some radius rc and acquires a vertical position, will not return the center of gravity on the axis of symmetry A-A (Fig. 7d). So in reality in the region c the spine rotates at a greater angle so that the axis of the spine intersects the vertical line A-A (Fig. 8a).

At the same time the spine being under control of cerebellum and vestibular system tends to acquire vertical position thus bending in the region b over some radius rb (Fig. 8b). In this position the center of gravity will be projected close to the center of supportive area, maintaining equilibrium of the body. However, the resulting tilt is not physiological, so it is reflexively corrected through bending of the spine in the region a over some radius ra (Fig. 8c), and the head also reflexively tends to turn so that the line of eyes would take maximally horizontal position.

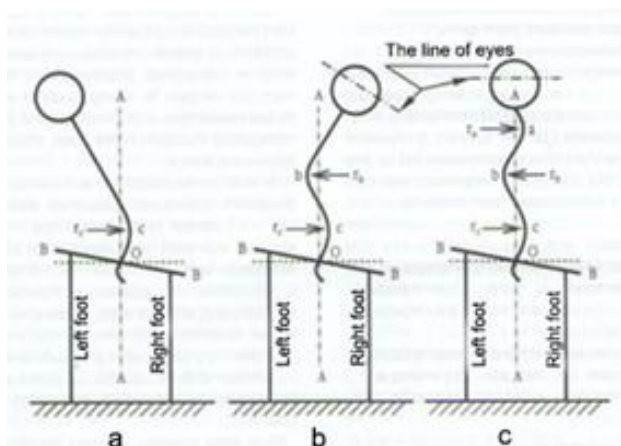


Figure 8. Curvature of the spine with impairment of balance.

Spinal deformity is not limited only to lateral curvature. Simultaneously separate vertebrae are turning about their axes – that is what we call rotation, resulting in subsequent reversal of separate segments of the spine – its torsion.

Due to the processes described above typical zones of the spine are formed – a, b and c that correspond to cervical, thoracic and lumbar regions where the vertebrae rotate relative to each other in a vertical plane (Fig. 9).

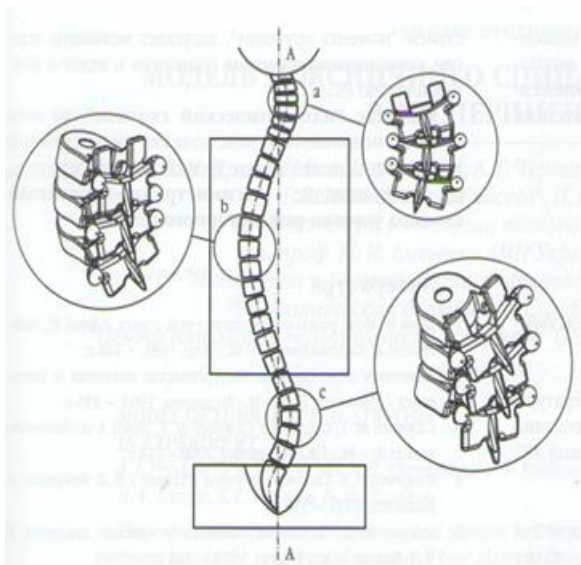


Figure 9. Regions of typical curvatures of the spine in an adult human with anatomically normal sacrum. Shortening of the right leg.

However, considering the fact that in all individuals up to 24 to 25 years of age and in 20-25% of older subjects sacral vertebrae are unfused (lumbarization), in lateral curvature of the spine fifth lumbar and upper sacral vertebrae also rotate relative to each other in some region d (Fig. 10). Thus, the fourth zone of rotational displacement of vertebrae is formed.

The degree of torsion of vertebrae around their axes depended on:

- The level of rotation;
- Strength of spinal muscles;
- Elastic properties of bony and cartilaginous tissue;
- Comorbid diseases of the skeleton;
- Endocrine dysfunctions, etc.

According to the laws of mechanics (“torsional moment” or torque), in each region of the spine, e.g. cervical, thoracic or lumbosacral, rotational displacement of vertebrae on the top of the curvature of each segment and mutually antithetical displacement of adjacent vertebrae were observed (Fig. 11).

These displacements may be explained with the tendency of an organism to preserve vertical position of the body, or, in other words, to ensure stability of the vertical structure – the spinal column. This is the reflection of the basic laws of mechanics.

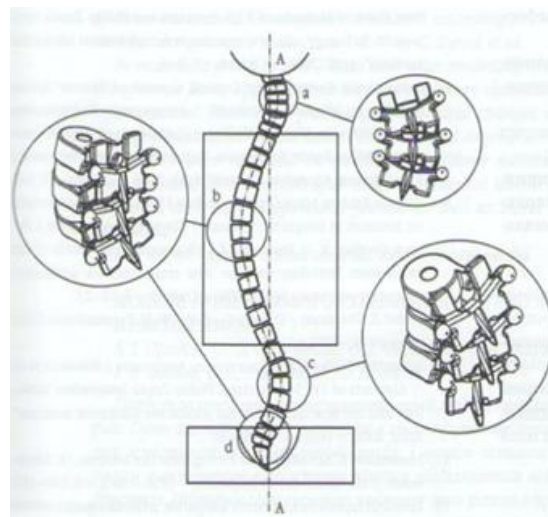


Figure 10. Regions of typical curvatures of the spine in unfused sacral vertebrae. Shortening of the right leg.

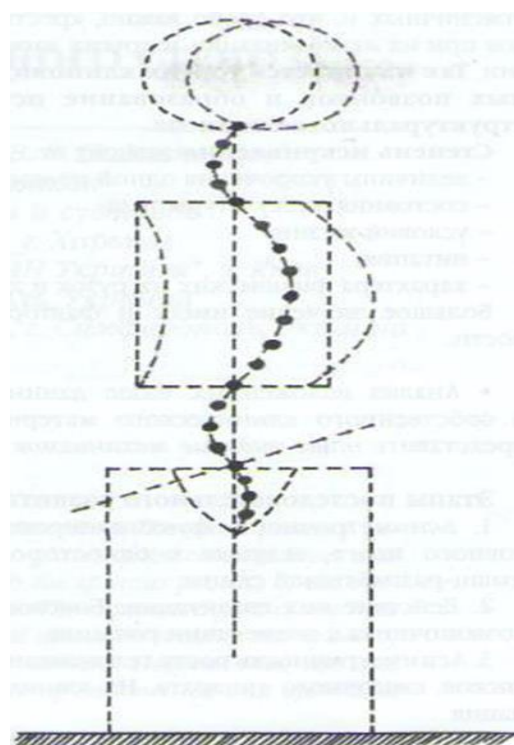


Figure 11. Schematic presentation of changes in body position in lateral bending of the trunk in equal length of lower extremities: •Vertical position of the body in equal length of lower extremities; •Deformation of the body in pelvic tilt due to shortening of the left leg; •Zones of rotational displacement of vertebrae at the top of segment curvature; •Zones of mutually antithetical displacement of vertebrae.

We shall consider another important fact. Already in early childhood and adolescence during the active development of the spinal skeleton in the tilt-rotated position (in zones of its maximal curvature), vertebral bodies and processes, intervertebral discs and ligamentous apparatus acquire an asymmetrical structure. As a result, dynamic stability of the spine is impaired and zones of instability in each segment of the spine are formed.

In turn, formation of these zone of instability leads to the situation when even a small pelvic tilt is sufficient to cause (in accordance with the action of the laws of classical mechanics) rotational displacement of vertebrae in these regions of the spine under the influence of "torsional moment"; then, cervical, thoracic, lumbar, and sacral vertebrae begun to turn around their axes in the presence of lumbarization and other types of dysplasia. Thus, torsion of wedge-changed vertebrae begins and true or structural scoliosis is formed.

Degree of curvature depends on the following:

- Degree of leg shortening;
- Condition of the body musculature;
- Living conditions;
- Nutrition;
- Type of physical activities, etc.

Hereditary factors are also of great importance.

- Analysis of the above data and our own clinical material allowed us to make our own considerations on the mechanisms of IS.

Subsequent stages of is

1. Asymmetrical functioning of cerebral cortex leads to unilateral spasm of spinal extensors.
2. Effect of gravity. Lateral curvature of the spine with elements of rotation.
3. Asymmetric growth of the vertebral bodies, processes, discs and ligaments. Wedge-shaped deformation.
4. Impairment of the dynamic equilibrium of the spine with formation of zones of instability on the top points of the curvatures of each segment.
5. Torsion of vertebrae within the instability zones due to "torsional moment" (laws of mechanics).

This mechanism of development of lateral curvature of the spine has regular nature and does not depend on gender, age and nationality of the patient.

The statement that we have formulated – "Consistent regularity of scoliosis development based on zones of instability in all its regions, occurring as a consequence of unilateral hyper tonus of spinal muscles, which is associated with asymmetric functioning of cerebral hemispheres" was recognized as scientific discovery and was awarded by Ukrainian Academy of original ideas; diploma #5 was issued (21.02.2008).

CONCLUSIONS

1. Idiopathic scoliosis is caused with regular, genetically determined, asymmetric structure of the human body, particularly, the brain.
2. Impairment of dynamic equilibrium of the spine in zones of instability associated with increasing asymmetry of musculature under the influence of "torsional moment" induces torsion of wedge-changed vertebrae and leads to IS.

3. The term "idiopathic scoliosis", e.g. lateral curvature of the spine of unknown origin, from our point of view should be replaced with other term – "asymmetrically-muscular scoliosis of conditioned reflex origin".

Author Contributions: LSVV, SAV, TGV: Research of the literature, Patient examinations, Manuscript preparation and revisions.

Financial & competing interest's disclosure: The authors have no relevant affiliations or financial involvement with any organisation or entity with a financial interest in or financial conflict with the subject matter or materials discussed in the manuscript. This includes employment, consultancies, honoraria, stock ownership or options, expert testimony, grants or patents received or pending, or royalties.

Conflict of interest: The author declared no potential conflicts of interest with respect to the research, authorship, and/or publication of this article. This research did not receive and specific grant from funding agencies in the public, commercial, or not-for-profit sectors.

REFERENCES

1. Bloom F. Brain, Mind and Behavior / F. Blum, A. Leiserson, L. Hofstadter. – М., 1988. – 248р. (Блум Ф. Мозг, разум и поведение / Ф. Блум, А. Лейзерсон, Л. Хофстедтер. – М.: Мир, 1988. – 248 с).
2. Movshovich IA. Scoliosis. Surgical anatomy and pathogenesis / IA Movshovich. - М., Medicine, 1964. – 255pp. (МОВШОВИЧ И. А. Сколиоз. Хирургическая анатомия и патогенез / И. А. Мовшович. – М.: Медицина, 1964. – 255 с).
3. Sampiev MT. Scoliosis / MT Sampiev, AA Laka, NV Zagorodny. - M. GEOTAR Media, 2008. – 144pp. (Сампиев М. Т. Сколиоз / М. Т. Сампиев, А. А. Лака, Н. В. Загородний. – М.: ГЭОТАР-Медиа, 2008. – 144 с).
4. Fishchenko VY. Scoliosis: a scientific publication / VY Fishchenko. - Makeevka, 2005. – 550pp. (Фищенко В. Я. Сколиоз: научное издание / В. Я. Фищенко. – Makeevka, 2005. – 550 с).
5. Chaklin VD. Pathological anatomy, clinical features and treatment of scoliosis / VD Chaklin. - M. Medgiz, 1958. – 340pp. (Чаклин В. Д. Патология, клиника и лечение сколиоза / В. Д. Чаклин. – М.: Медгиз, 1958. – 340 с).
6. Schantz AM. Practical Orthopedics: translated from German / AM Schantz. - M. Medgiz, 1933. – 410pp. (Шанц А. М. Практическая ортопедия : пер. с нем / А. М. Шанц. – М.: Медгиз, 1933. – 410 с).
7. Aage Indabl. The role of muscles in the development of scoliosis, an experimental study in a porcine model / Aage Indabl, Sten Holm // Abstracts of 11th International Philip Zorab Symposium "Aetiology and new treatments for adolescent idiopathic scoliosis". April, 2006. – Oxford. – P. 2-3.
8. Annapoorna Kuppuswamy. Cortical Control of Erector Spinae Muscles in Idiopathic Scoliosis / Annapoorna Kuppuswamy, Peter H. Ellaway, Alison H. McGregor // Abstracts of 11th International Philip Zorab Symposium "Aetiology and new treatments for adolescent idiopathic scoliosis". April, 2006. – Oxford. – P. 4-5.
9. Clayton J. Adam. Askin Gravity-induced Torsion and Intravertebral Rotation in Idiopathic Scoliosis / Clayton J. Adam, Mark J. Percy, Geoffrey N. // Abstracts of 11th International Philip Zorab Symposium "Aetiology and new treatments for adolescent idiopathic scoliosis". April, 2006. – Oxford. – P. 22-23.
10. Hubel D. The Brain / D. Hubel. – N. Y.: W. H. Freeman and Company. – 1979. – 321 p.

11. Idiopathic Scoliosis and Basicranium Asymmetry / Rousie D. et al. // Abstracts of 11th International Philip Zorab Symposium “Aetiology and new treatments for adolescent idiopathic scoliosis”. April, 2006. – Oxford. – P. 56-57.
12. Lindemann K. Aetiologie und Pathogenese der Scoliose / K. Lindemann // Handbuch der Orthopädie. – 1958. – 1 2. – S. 160–187.
13. Perinatal factors in adolescent idiopathic scoliosis – questionnaire study / Chaloupka R. et al. // Abstracts of 11th International Philip Zorab Symposium “Aetiology and new treatments for adolescent idiopathic scoliosis”. April, 2006. – Oxford. – P. 12-14.
14. Schmidt R. F. Human Physiology / R. F. Schmidt, G. Thews. – N. Y. : Springer-Verlag, 1983. – 797 p.
15. Stillwell D. Structural deformities of vertebrae / D. Stillwell // The Journal of bone and joint surgery. – 1962. – Vol. 44-A. – P. 611–634.