

## Ileosigmoid knotting: Case report and literature review

Amgad Abdou Hanna<sup>1</sup>, Abdul-Rahman Radwan Al-Shobaki<sup>1\*</sup>, Khalid Al-Hamadani<sup>1</sup>, Fatema Al-Iwati<sup>1</sup>, Hader M. Elmaghraby<sup>1</sup>, Yasser Abbas<sup>1</sup>

<sup>1</sup> Dept. of General Surgery, Khoula Hospital, Sultanate of Oman

\* **Corresponding Author:** Abdul-Rahman Radwan Al-Shobaki **E-mail:** aelshobaki@gmail.com

### ABSTRACT

**Objective:** Ileosigmoid knotting (ISK) is the wrapping of the ileum around the sigmoid colon and its mesentery or vice-versa. ISK is a rare cause of bowel obstruction in general and rare during pregnancy.

**Case:** We present a case of ISK, a Pregnant lady 29th weeks gestation, which was treated successfully in our institution – Khoula Hospital – Muscat - Sultanate of Oman.

**Keywords:** Ileosigmoid, knotting, pregnancy

### INTRODUCTION

Ileosigmoid knotting (ISK) is the wrapping of the ileum around the sigmoid colon and its mesentery or vice-versa (1).

ISK is a rare cause of bowel obstruction in general, and a rare diagnosis during pregnancy. ISK Diagnosis is very difficult preoperatively due to the condition's rarity, the difficult clinical assessment during pregnancy and its atypical radiographic features. Exploration laparotomy uses to reach the final diagnosis and manage refractory bowel obstruction with or without peritonitis. Most cases manage by resection with stoma apart from a few cases handled without a stoma.

To our knowledge, this is the First ISK case to be published from Oman.

### CASE

Thirty-two years old woman, primigravida at 29 weeks of pregnancy presented to the obstetric emergency room in our institution with history of generalized abdominal pain associated with nausea and repeated vomiting with absolute constipation lasting for a day. She had no vaginal bleeding or discharge and no significant past medical or surgical history.

Initial examination at the time of presentation: The patient was alert, conscious and oriented, blood pressure was 110/70 mmHg, heart rate 74 beats/minute, afebrile.

The abdomen was soft, cervix posterior os closed, and ultrasound showed a breech alive fetus.

Laboratory investigations at presentation were within normal levels.

Patient was deemed to in preterm labour pain, hence was admitted overnight for observation.

Upon follow up next day, the patient had repeated episodes of vomiting. Abdominal pain markedly increased in intensity. Her heart rate increased to 140 beats /minute, Maintaining her blood pressure, the temperature of 37.7 °C.

Abdominal examination revealed marked distension, generalized tenderness with guarding and rigidity, Absent Bowel sounds. Digital rectal examination (DRE) showed an empty ballooned rectum.

### Review Article

**Received** 02-01-2022

**Accepted** 13-03-2022

**Available Online:** 14-03-2022

**Published** 30-03-2022

Distributed under  
Creative Commons CC-BY-NC 4.0

**OPEN ACCESS**



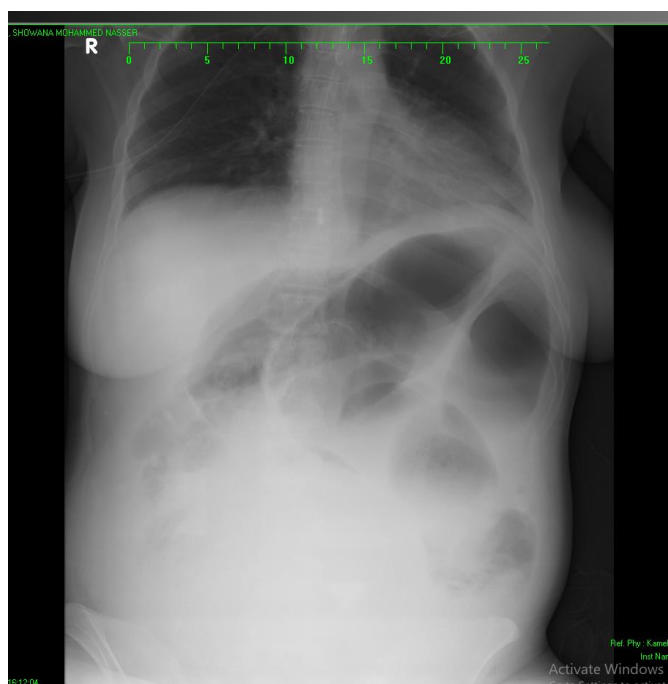
Laboratory investigations repeated and showed marked leukocytosis (from  $10.12 \times 10^3/\text{uL}$  to  $24 \times 10^3/\text{uL}$ ).

Radiological investigations:

- Plain lower chest and abdominal X-rays showed dilated large bowel loop with coffee bean sign and no free gas under the diaphragm.

- Contrast-enhanced CT scan of the abdomen and pelvis showed a significant amount of free fluid involving all peritoneal cavities. Markedly dilated small bowel loop noted at the left hypochondria and showing air-fluid level with decreased wall enhancement and pneumatosis with fecalization. Superior mesenteric vessels were seen stretched and swirled in the left para duodenal space.

The large bowel appeared normal diameter and showed normal wall enhancement. Pneumoperitoneum not defined. Gravid uterus showed with a single fetus.



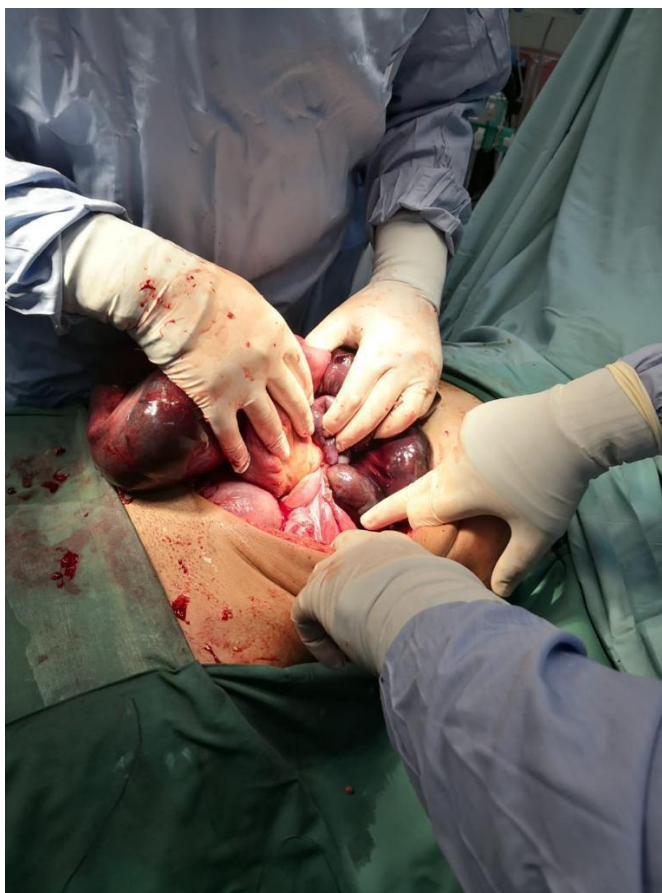**Figure 1:** Plain abdominal x-ray – supine position.

After proper resuscitation, the decision was made to take the patient for exploration laparotomy. Consent was taken for a simultaneous caesarean section as the baby was the breech presentation, and the mother is primigravida. For most cases caesarean will be required in case of premature delivery after surgery (which has high probability)

Exploration of the abdominal cavity was done.

**Intraoperative Findings:** After 150 cm from DJ flexure, all rest of bowel is gangrenous till 10 cm from the ileocecal valve.

The entire gangrenous segment is twisted around its mesentery surrounding a dilated gangrenous sigmoid volvulus. Abdominal cavity had full of serosanguinous fluid.



**Figure 2:** Intra operative picture showing the Ileosigmoid knot

CS was done by the obstetric team delivering the alive male baby.

Resection of all the gangrenous segments of the small bowel was operated, with end-to-end hand-sewn anastomosis. Then resection of the sigmoid colon was done, side to side colo-rectal anastomosis was done using linear cutter stapler.

Postoperatively, the patient was shifted intubated and ventilated to ICU, in septic shock.

Gradually patient recovered, was extubated in the 9th post-op day, passed a motion in the 11th post-op day and shifted out of ICU in the same day, discharged home at the 15th post-op day in good general condition after returning to normal feeding and bowel motion habits. The delivered baby was intubated for one day, admitted to SCBU, discharged from the hospital in good condition after 34 days.

The patient was followed up in the OPD clinic for five weeks post-operative, and she was doing well, has no complaints, tolerating a normal diet and passing motion normally.

## DISCUSSION

The Ileosigmoid knot was first described in 1845. It is common in Africa, Asia and Middle East. Males are more commonly affected than females (4:1), usually around the age of 40 years (range 4-90 years). ISK in pregnancy is a rare condition. There are only 9 reported cases of ISK in pregnancy in the literature between 1967 and 2009; with the incidence of ISK in pregnancy ranging from 3.2% to 5.9% of all ISK cases and 12.5% to 36.4% of ISK cases in female patients (2).

Pathophysiology of ISK is not fully understood, but it is being hypothesized that Loops of the small bowel may twist around its mesentery then by progressive peristalsis, this closed-loop wrap around sigmoid volvulus.(2) There are secondary factors besides the anatomical factors mentioned above, such as late pregnancy, trans-mesenteric herniation, Meckel diverticulitis with the band, and ileocecal intussusceptions (3).

<b>Type I</b>	The ileum (active component) wraps itself around the sigmoid colon (passive component) in a clockwise or anticlockwise direction.	(Type A when clockwise and type B when anticlockwise).
<b>Type II</b>	The sigmoid colon (active component) wraps itself around a loop of ileum (passive component) in a clockwise or anticlockwise direction.	
<b>Type III</b>	The ileocecal segment (active component) wraps itself around the sigmoid colon (passive component).	

**Notes:** Reproduced from Alver O, Ören D, Tireli M, Kayabaşı B, Akdemir D. Ileosigmoid knotting in Turkey. Review of 68 cases. *Dis Colon Rectum*. 36(12):1139–1147. <https://doi.org/10.1007/BF02052263><sup>6</sup>

The predominant symptoms and signs of presentation include abdominal pain and tenderness (100%), abdominal distension (94% to 100%), nausea and vomiting (87% to 100%), rebound tenderness (69%), and shock (0% to 60%) (2, 5, 6, 7).

Upon review of literature, we found very few reported cases in the English language describing ISK. Multiple factors made our case different than other cases, i.e. simultaneous caesarean section was done delivering alive male baby 29 weeks gestational age. That decision was taken because the presentation was breech. “We found that non-obstetric surgery during pregnancy was associated with a higher risk of adverse birth outcomes. We estimated that every 287 surgical operations were associated with 1 additional stillbirth, every 31 operations associated with 1 additional preterm delivery, every 39 operations associated with 1 additional low birth weight baby, every 25 operations associated with 1 additional caesarean section, and every 50 operations associated with 1 additional long inpatient stay” (8).

The risk that a breech baby will need caesarean section in a primigravida mother is 62% (9).

So our decision was clear from the beginning to perform both surgeries in one session.

We have noticed a contradiction between reporting well-enhanced non dilated large bowel while we found that the sigmoid colon was dilated and gangrenous mandating resection, hence surgical teams should be cautious in correlating radiological findings and having a high index of suspecting bowel ischemia in similar scenarios.

Another unique feature in our case management is that resection for both small bowel and sigmoid colon done, with direct single-stage anastomosis was done after proper on table lavage. By doing this, we are following the recommendations of all recent textbooks and studies in general surgery, which offered a better quality of life and reduced surgical morbidity.

**Author Contributions:** AAH, ARA, KA, FA, HME, YA: Study design, Patients examination, Surgical operation Literature review, Data collection and/or processing, Analysis and/or interpretation, ARA: Article Writing, Revision

**Acknowledgments:** None

**Conflict of interest:** The author declared no potential conflicts of interest with respect to the research, authorship, and/or publication of this article. This research did not receive a specific grant from funding agencies in the public, commercial, or not-for-profit sectors.

**Ethical approval:** The study was conducted according to the guidelines of the Declaration of Helsinki and approved by Local Ethical Committee. All procedures performed in studies with human participants met the ethical standards of the Institutional Research Commission and the 1964 Declaration of Helsinki and its subsequent amendments or comparable ethical standards.

## REFERENCES

- Atamanalp SS. Ileosigmoid knotting. *The Eurasian journal of medicine*. 2009 Aug;41(2):116.
- Maunganidze AJ, Mungazi SG, Siamuchembu M, Mlotshwa M. Ileosigmoid knotting in early pregnancy: A case report. *International journal of surgery case reports*. 2016 Jan 1;23:20-2..
- Machado NO. Ileosigmoid knot: a case report and literature review of 280 cases. *Annals of Saudi medicine*. 2009 Sep;29(5):402-6.
- Mandal A, Chandel V, Baig S. Ileosigmoid knot. *Indian Journal of Surgery*. 2012 Apr;74(2):136-42.
- Alver O, Ören D, Tireli M, Kayabaşı B, Akdemir D. Ileosigmoid knotting in Turkey. *Diseases of the colon & rectum*. 1993 Dec;36(12):1139-47.
- Atamanalp SS, Oeztuerk G, Aydinli B, Yildirgan MI, Başoğlu M, Öeren D, KANTARCI AM. A new classification for ileosigmoid knotting. *Turkish Journal of Medical Sciences*. 2009 Sep 23;39(4):541-5.

7. Shepherd JJ. Ninety-two cases of ileosigmoid knotting in Uganda. *Journal of British Surgery*. 1967 Jun;54(6):561-6..
8. Balinskaite V, Bottle A, Sodhi V, Rivers A, Bennett PR, Brett SJ, Aylin P. The risk of adverse pregnancy outcomes following nonobstetric surgery during pregnancy: estimates from a retrospective cohort study of 6.5 million pregnancies. *Annals of Surgery*. 2017 Aug 1;266(2):260-6.
9. Karning RK, Bhanu BT. Mode of delivery and outcome of breech presentation: a prospective observational study in a tertiary centre. *International Journal of Reproduction, Contraception, Obstetrics and Gynecology*. 2017 Aug 1;6(8):3409-14.