

Case of BRAF mutant Erdheim-Chester disease presenting with multisystem involvement: A case report

Nang Hseng Kyio^{1*}, Tugce Kiran², Ali Eser³, Guven Cetin³, Cumali Karatoprak¹

1 Bezmialem Vakif University Faculty of Medicine, Dept of Internal Medicine, 34093, Fatih, Istanbul, TR

2 Bezmialem Vakif University Faculty of Medicine, Dept of Pathology, 34093, Fatih, Istanbul, TR

3 Bezmialem Vakif University Faculty of Medicine, Dept of Hematology, 34093, Fatih, Istanbul, TR

* Corresponding Author: Nang Hseng Kyio E-mail: nangkyio@gmail.com

ABSTRACT

Objective: Erdheim-Chester disease is a rare form of non-Langerhans cell histiocytosis of unknown etiology. It is a multisystemic disease that can involve bones, skin, brain, retroperitoneum, cardiovascular system, endocrine system, and lungs. Diagnosis is made by clinical findings, imaging results, and histopathological examination. BRAFV600E (B-rapidly accelerated fibrosarcoma gene) mutation is found in more than half of the cases. When Erdheim-Chester disease is not considered the differential diagnosis, it is not possible to diagnose and treat. In this case report, an Erdheim-Chester case with symptomatic, multisystem involvement, BRAFV600E mutation, and initiated vemurafenib treatment is presented in the light of literature data.

Keywords: Bone pain, non-Langerhans cell histiocytosis, Erdheim-Chester Disease, vemurafenib, case report

INTRODUCTION

Erdheim-Chester disease (ECD) was first described as lipid granulomatosis in 1930 by Jacob Erdheim and William Chester (1, 2). The cases are generally diagnosed between the ages of 40-70. It is slightly more common in men (2-4).

Clinical findings are related to the involved organ (2, 5). The skeletal system is involved in 95% of the cases. Bilateral cortical osteosclerosis in long bones involving the diaphysis and metaphysis strongly suggests ECD. The axial system is generally preserved. Findings of 18-FDG PET-CT are highly specific. Patients often complain of bone pain (2, 3, 5).

Cardiovascular involvement is detected in at least 50% of patients (2, 5). Retroperitoneal fibrosis is seen in nearly half of the cases, especially around the kidneys and ureters. Central nervous system involvement is detected in approximately half of the cases (6).

Diabetes insipidus as a result of pituitary involvement and exophthalmos as a result of periorbital involvement is seen in 20-30% of cases. Particularly pleural and mediastinal involvement can be seen in the respiratory system. Lesions in the skin, xanthelasma in the eyelids and periorbital region are common. Arterial involvement can be seen in 50-80% of cases (2, 5). Additionally, myeloid neoplasia develops in approximately 10% of the cases (2). The biopsy is required for the diagnosis of ECD.

The examination shows mixed infiltration rich in histiocytes and rare Touton giant cells and fibrosis. Histiocytes are CD 68 positive and CD 1a negative (3, 5, 7). More than half of the cases have the BRAFV600E (B-rapidly accelerated fibrosarcoma gene) mutation (3, 4, 7, 8). Corticosteroids, interferon (INF), anti-cytokine therapy, and targeted therapies, BRAF inhibitor, vemurafenib and MEK inhibitors can be used in treatment (1, 2, 8).

While Non-Langerhans cell histiocytosis constitutes the rarely seen disease group, we wanted to present a case of ECD, which is one of its subgroups and because of the fact that only a few cases have been reported in the world.

Case Report

Received 16-01-2021

Accepted 01-02-2021

Available Online: 06-02-2021

Published 24-02-2021

Distributed under
Creative Commons CC-BY-NC 4.0

OPEN ACCESS



CASE

A 48-year-old male patient has complaints of bone pain and fatigue for 15 years. Thirteen years ago, the patient, who applied to a hospital with these complaints, was diagnosed with histiocytosis X and was given steroid therapy for 10 months. His treatment was discontinued due to the development of iatrogenic Cushing in his follow-up, and central Diabetes Insipidus developed during his follow-up in the hospital. The patient, whose pain in the hip bones was investigated, was diagnosed with steroid-induced avascular necrosis. The patient is first monitored and then operated on 2 years later. During this period, the patient's complaints repeated millitantly. He applied to our hospital with the complaint of extreme fatigue. The laboratory tests in his application are shown in (Table 1).

Table 1: Laboratory results of the patient

	Before treatment	After treatment	Normal range
WBC (10 ³ /uL)	6,7	8,7	4.6-10.2
Hg (g/dl)	7,6	12,7	12.2-16.2
Hct (%)	25,49	40,76	35.5-48
Plt (10 ³ /uL)	331	228	142-424
Glucose (mg/dl)	90	89	70-105
AST (U/L)	94	16	5-34
ALT (U/L)	98	13	0-55
Total Bilirubin (mg/dl)	0,41	0,19	0.2-1.2
Creatinine (mg/dl)	0,44	0,71	0.57-1.11
CRP (mg/dl)	164	69	<0.5
ESR (mm/h)	72	36	0-20
Albumin (g/dL)	2,5	4,3	3.5-5
LDH (U/L)	295	209	125-220
Na (mmol/L)	140	141	135-145
K (mmol/L)	4,5	4,3	3.5-5.1
Ca (mg/dl)	8	9,1	8.4-10.2

WBC: white blood cell, Hg: hemoglobin, Hct: hematocrit, Plt: platelet, AST: aspartate aminotransferase, ALT: alanine aminotransferase, CRP: C-reactive protein, ESR: erythrocyte sedimentation rate, LDH: lactate dehydrogenase, Na: sodium, K: potassium, Ca: calcium

In thoracic computed tomography (CT), low-density nodules with a diameter of 5.5 mm are present in both lung parenchyma, the larger of which is in the lower lobe of the left lung, laterobasal segment. Pleural thickening was observed in the right lung. Spleen size was 155 mm in abdominal CT, and a 10 mm hypodense lesion was observed in the lateral middle part of the spleen. There was an appearance of hypodense soft tissue around both kidneys reaching a thickness of 20 mm on the right and 19 mm on the left. 18-FDG PET/CT imaging showed areas of hypermetabolism in the cranium, sphenoid bone, left frontal bone, bilateral humerus, right iliac bone, adjacent sacroiliac joint, left acetabulum ceiling, and bilateral femur in favor of the involvement of the primary lytic-sclerotic disease (SUV Max:10.1), paravertebral mild hypermetabolic pleural thickenings in the right hemithorax, increased retroperitoneal, hypermetabolic density in the vicinity of the bilateral kidney, increased kidney size, and hepatosplenomegaly (Figure 1). When the patient was evaluated cardiologically, fibrotic aortic and mitral valves, minimal mitral, aortic, and tricuspid regurgitation were detected on echocardiography. The ejection fraction was calculated to be 60%. Erythematous antral gastritis was determined in gastroscopy examination. No pathology was found in the colonoscopic examination. The biopsy was taken from the xanthomatous lesion around the eye. A trucut biopsy was performed from the soft tissue around the kidney with imaging guidance. Pathology was evaluated as compatible with ECD. The BRAF mutation examined was also found to be positive in support of ECD (Figure 2). Vemurafenib was started because studies were showing that it is more effective on the patient's multisystem involvement including the central nervous system, the development of side effects to previous steroid treatment, and the detection of positive BRAF mutation (9, 10). Vemurafenib treatment dose was started as 960 mg/ day. An improvement in clinical and laboratory values was detected in the first 3 months of the patient's follow-up (Table 1). The patient, whose general condition is stable, comes for a checkup every 3 months.

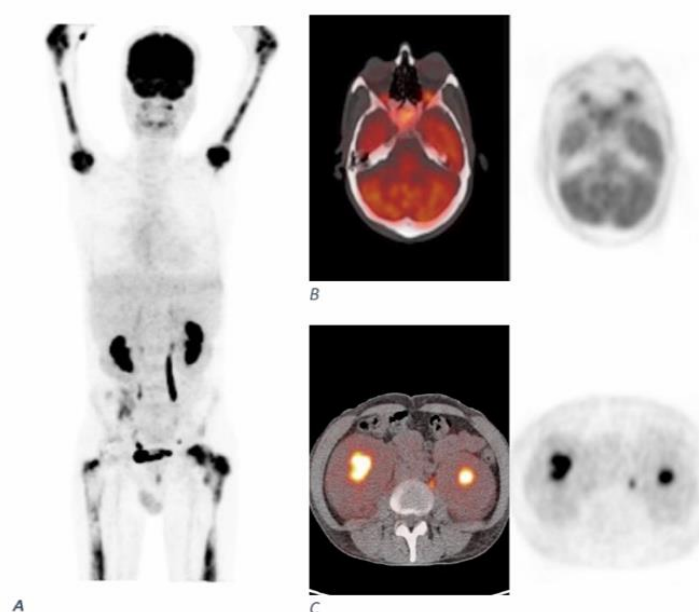


Figure 1. Positron emission tomography (PET) scan showing high pathologic uptake 18F- fluorodeoxyglucose in multiple sclerotic bone lesions (A), cranium (B) and perirenal soft tissue (C).

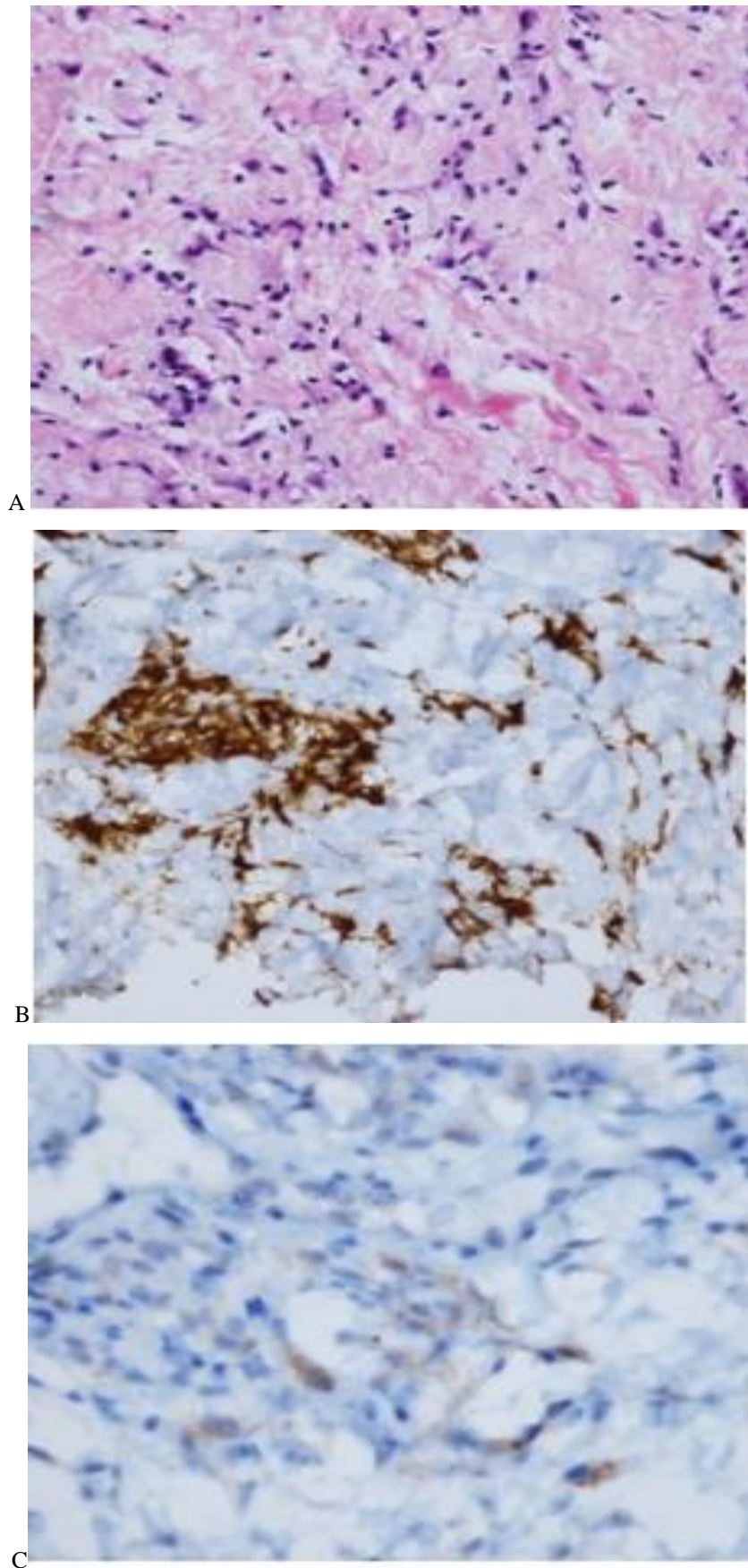


Figure 2. **A:** In samples taken from perirenal soft tissue, histiocytic cells with foamy cytoplasm forming small groups in collagenized connective tissue were noted. **B-C:** The described histiocytic cells showed immunohistochemically positive immunoreactivity with CD163 and BRAF. The result of the V600E mutation in the BRAF gene applied by the real-time PCR method is positive. The mutation is present.

DISCUSSION

Erdheim Chester disease can affect many organs. Since the lesions are not specific to the disease, patients may be diagnosed late (4, 8). The main complaints of the patients are bone pain and fatigue. Weight loss, fever, and night sweats may also occur (1). In our patient, the first application reason and the complaint during the period were bone pain and fatigue. Laboratory findings are not specific to the disease. However, sedimentation and high C-reactive protein (CRP) are detected in most patients (1, 4). Both of the values were high in our patient. Anemia findings observed in our patient are related with chronic inflammation. Liver enzymes are elevated in 10% of patients (4). In our patient, liver enzymes that were normal at the beginning were found to be slightly elevated at the final examination. Imaging methods play a crucial role in diagnosis. Bone scintigraphy rather than direct radiography shows long bone lesions. CT is valuable for organ involvement. Particularly, perirenal fat tissue involvement and fibrosis, which is responsible for "hairy kidney" appearance, can be demonstrated by CT. Magnetic resonance imaging (MRI) is more suitable for central nervous system and cardiovascular system lesions (1, 4, 8). In our case, pituitary involvement was detected by MRI. 18 FDG-PET/CT is ideal for showing both skeletal system and soft tissue lesions (1, 4, 8). In addition, response to treatment can be followed by this method. Extensive bone involvement was determined with 18 FDG-PET / CT in our patient. Organ involvement and retroperitoneal involvement around the retroperitoneal kidney were also shown. Lymph node involvement is very rare in ECD (4). In our case, there was no finding of lymph node involvement.

Biopsy of pathological tissues is required to confirm the diagnosis of Erdheim-Chester disease. In order for the biopsies to be evaluated accurately in pathology, considerations about clinical and pre-diagnosis should be consulted with pathology. Biopsy can be performed on different areas of involvement such as bone, skin, retro-orbital and retroperitoneal region. Mixed infiltration rich in histiocytes and sparse Touton giant cells and fibrosis are seen. Histiocytes are CD68 positive and CD1a negative (1, 4, 7, 8). In our case, biopsies were performed from the xanthomatous lesion around the eye and perirenal tissue. In the biopsy sample taken, staining in histiocytes was CD68 (+) and CD1a (-), and staining was selected with BRAF in the lesions. The biopsies taken had features that could be compatible with Erdheim Chester. The prognosis of Erdheim Chester disease depends on the degree of the organ involved and the treatment given (9). Early diagnosis and timely initiation of correct treatment are important for patient's morbidity and mortality. With the increasing knowledge of the pathogenesis, BRAF and MEK inhibitors are used. Cases with a favorable response with vemurafenib therapy have been reported in patients with BRAF mutants (10, 11). In our case, in the third-month follow-up of vemurafenib treatment, clinical remission, increase in haemoglobin, and regression in inflammatory markers such as CRP and ESR were found (Table 1). In our case, diabetes insipidus, pituitary involvement, testicular insufficiency, diffuse bone involvement, xanthetasis in the skin, pleural thickening in the lungs, perirenal/retroperitoneal involvement, splenomegaly, hepatomegaly, and chronic anemia were detected. As in our

case where many organs are involved, defined ECD is limited in number. Its diagnosis is difficult due to its low awareness, extreme rarity and involvement of many different organs. When ECH disease is not known, it will not be possible to make a diagnosis and to give the correct treatment, even if there are typical kidney appearance and bone lesions. We wanted to present a very rarely found case to the literature and raise the awareness of the disease.

Author contributions: **NHK, CK;** Patient examination and project design, **TK;** Pathological examinations, **AE, GC;** Hematological tests, **NHK;** review of the literature, analyzes and writing of the manuscript.

Conflict of interest: The authors declared no potential conflicts of interest with respect to the research, authorship, and/or publication of this article. This research did not receive and specific grant from funding agencies in the public, commercial, or not-for-profit sectors.

Ethical issues: All authors declare originality of research.

REFERENCES

- Mazor RD, Manevich-Mazor M, Shoenfeld Y. Erdheim-Chester Disease: a comprehensive review of the literature. *Orphanet J Rare Dis.* 2013;8:137.
- Papo M, Emile JF, Maciel TT, Bay P, Baber A, Hermine O, et al. Erdheim-Chester Disease: a Concise Review. *Curr Rheumatol Rep.* 2019;21(12):66.
- Emile JF, Ablu O, Fraitag S, Horne A, Haroche J, Donadieu J, et al. Revised classification of histiocytoses and neoplasms of the macrophage-dendritic cell lineages. *Blood.* 2016;127(22):2672-81.
- Starkebaum G, Hendrie P. Erdheim-Chester disease. *Best Pract Res Clin Rheumatol.* 2020:101510.
- Abdelfattah AM, Arnaout K, Tabbara IA. Erdheim-Chester disease: a comprehensive review. *Anticancer Res.* 2014;34(7):3257-61.
- Pan Z, Kleinschmidt-DeMasters BK. CNS Erdheim-Chester Disease: A Challenge to Diagnose. *J Neuropathol Exp Neurol.* 2017;76(12):986-96.
- Ozkaya N, Rosenblum MK, Durham BH, Pichardo JD, Abdel-Wahab O, Hameed MR, et al. The histopathology of Erdheim-Chester disease: a comprehensive review of a molecularly characterized cohort. *Mod Pathol.* 2018;31(4):581-97.
- Goyal G, Heaney ML, Collin M, Cohen-Aubart F, Vaglio A, Durham BH, et al. Erdheim-Chester disease: consensus recommendations for evaluation, diagnosis, and treatment in the molecular era. *Blood.* 2020;135(22):1929-45.
- Diamond EL, Dagna L, Hyman DM, Cavalli G, Janku F, Estrada-Veras J, et al. Consensus guidelines for the diagnosis and clinical management of Erdheim-Chester disease. *Blood.* 2014;124(4):483-92.
- Fernández-Eulate G, Muñoz-Lopetegui A, Ruiz I, Urtasun MJBCRC. Vemurafenib as first-line therapy in BRAF-V600E-mutant Erdheim-Chester disease with CNS involvement. 2019;12(11).
- Haroche J, Cohen-Aubart F, Emile J-F, Arnaud L, Maksud P, Charlotte F, et al. Dramatic efficacy of vemurafenib in both multisystemic and refractory Erdheim-Chester disease and Langerhans cell histiocytosis harboring the BRAF V600E mutation. 2013;121(9):1495-500.

Copyright © 2021 The Author(s); This is an open-access article distributed under the terms of the Creative Commons Attribution License (<http://creativecommons.org/licenses/by/4.0>), (CC BY NC) which permits unrestricted use, distribution, and reproduction in any medium, provided the original work is properly cited. *International journal of Medical Science and Discovery.*